Interaktion mit dem Fach Radiologie

Beispiele aus der Thoraxdiagnostik

Zwei Konzepte 1 & 2
Beispiele
Interaktion

#1

1. "Intro" – 4:48
2. "White" – 6:07
3. "Yellow" – 6:55
4. "Orange" – 8:41
5. "Red" – 6:05
6. "Green" – 8:13
7. "Blue" – 6:36
8. "Electric Red" – 4:19
9. "Indigo" – 6:06
10. "Violet" – 9:04

#1

Schnee

Pflanzen

Wolken

Himmel

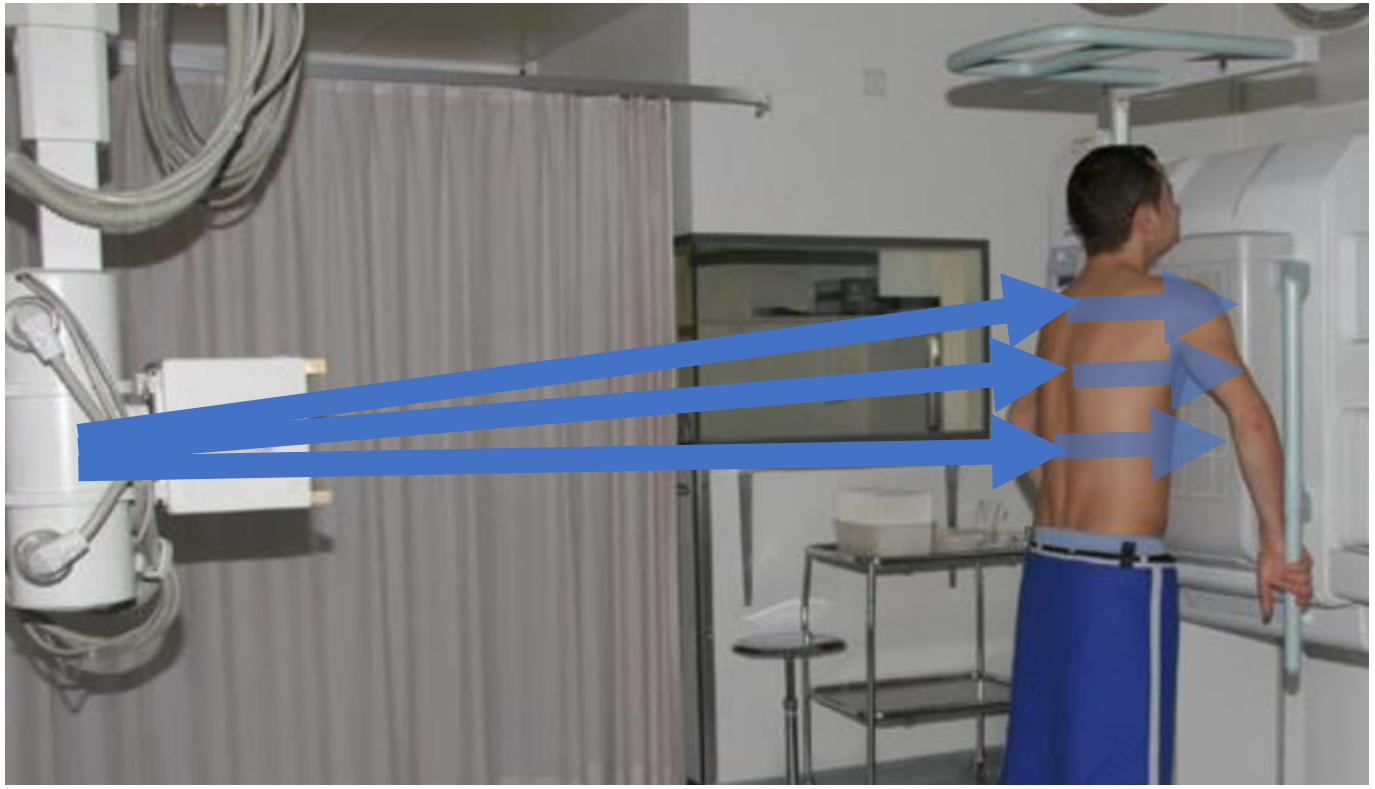

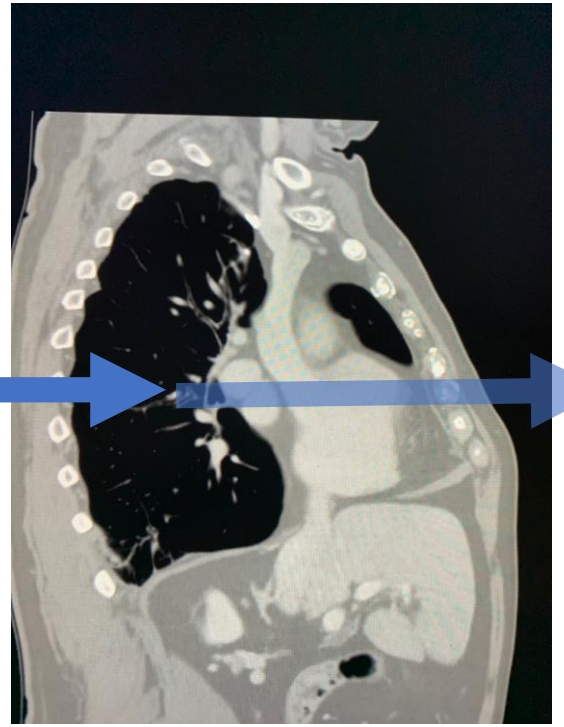

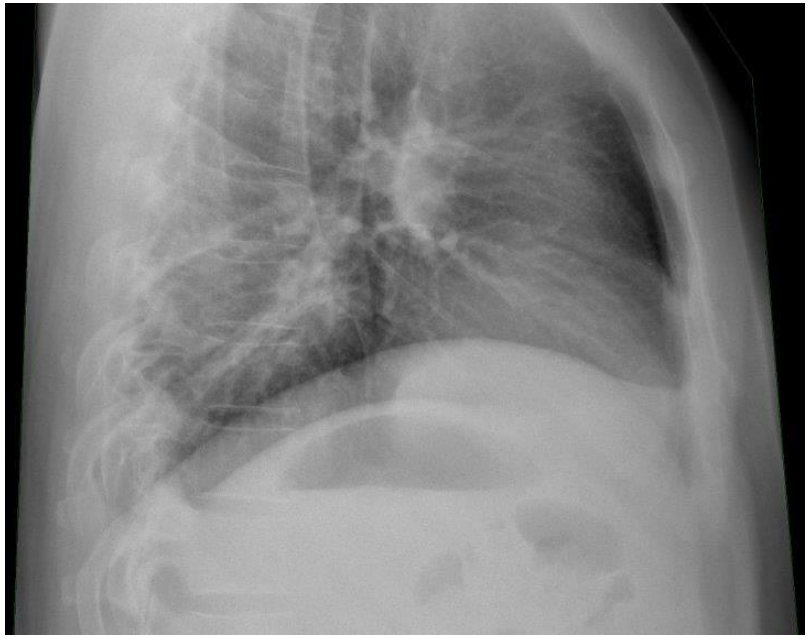

4

Schnee

Himmel

Wolken

Pflanzen

Calzium

Fett

Wasser

Luft

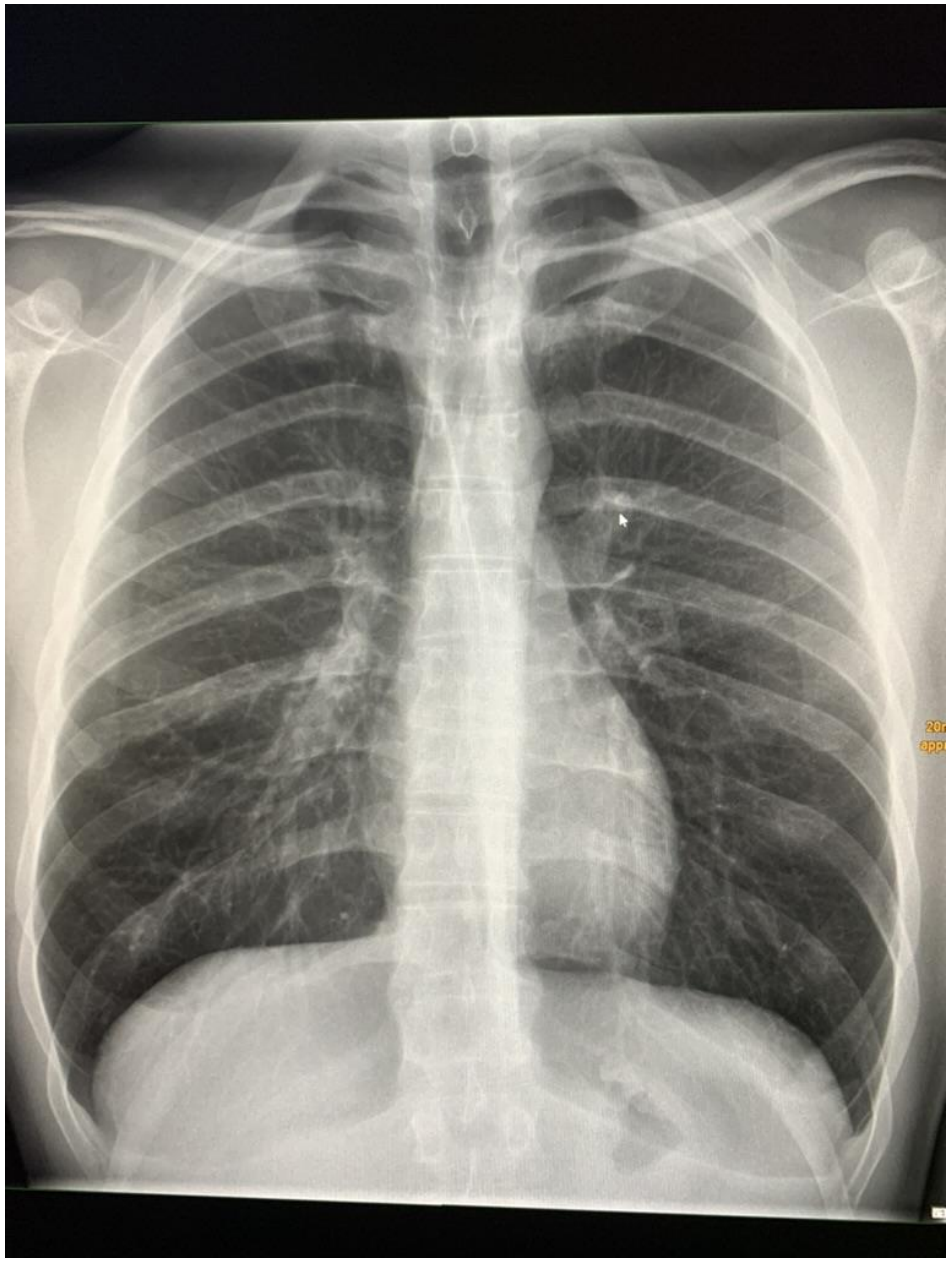

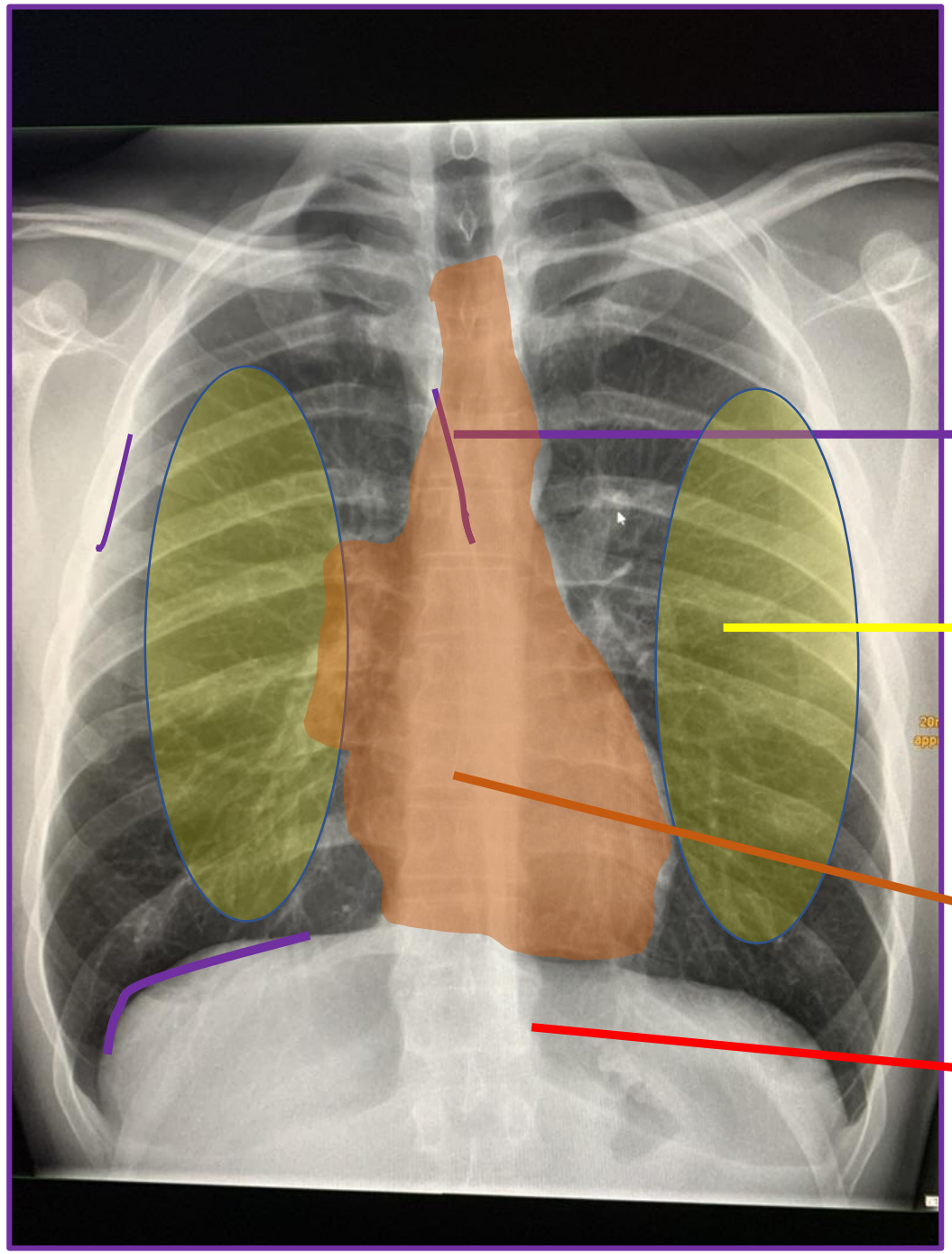

Pleura

Lunge

Mediastinum,Herz usw.

Knochen

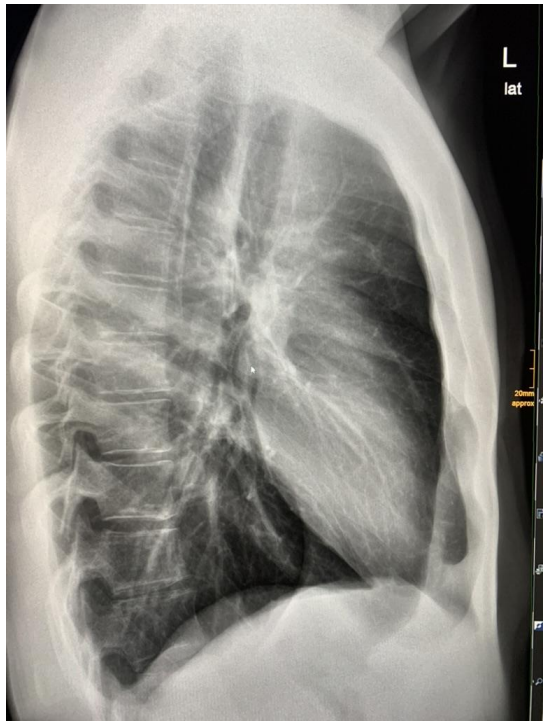

#2

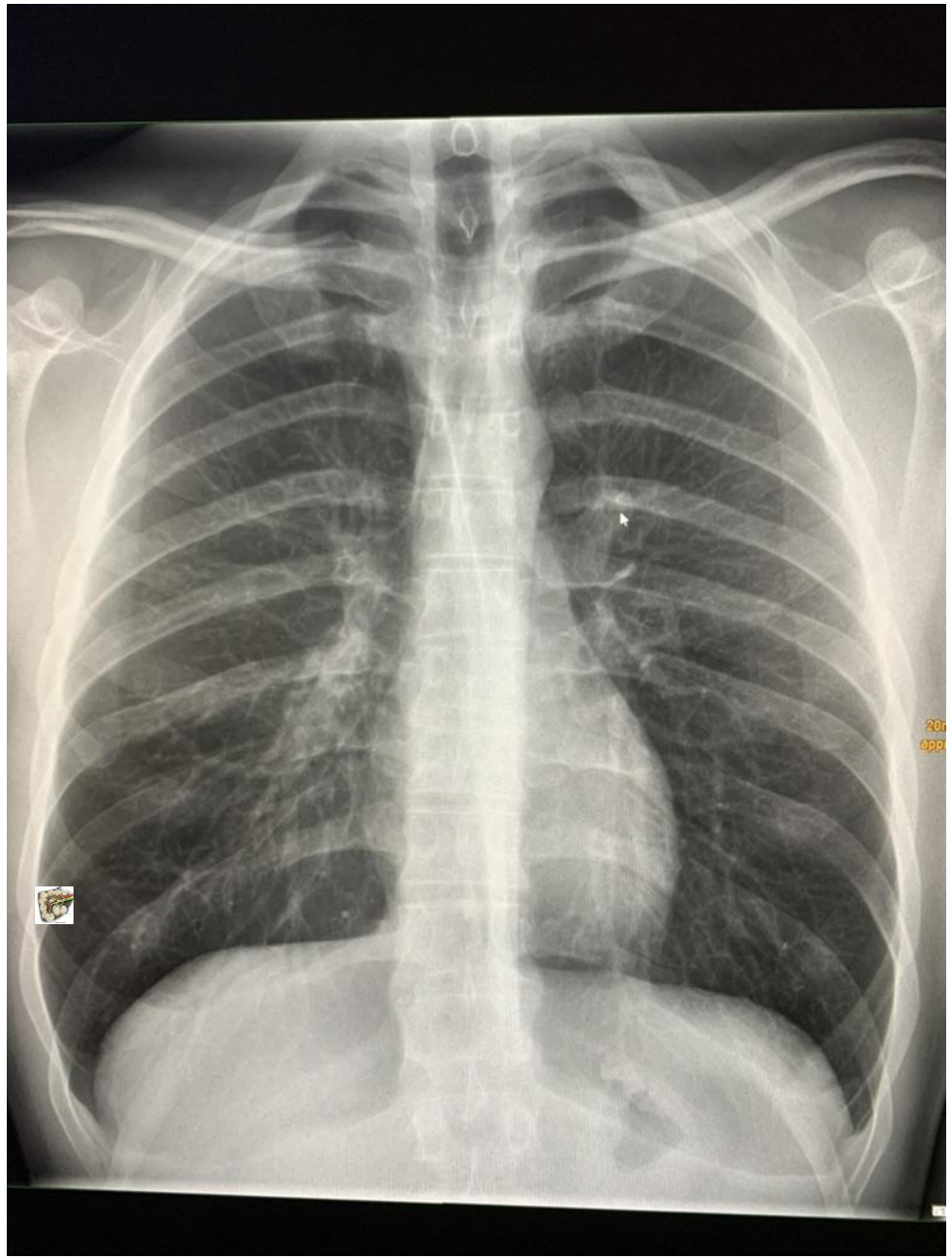

Sekundärer Lobulus

Distal des terminalen Bronchiolus

Respiratorische Broncioli

Acini



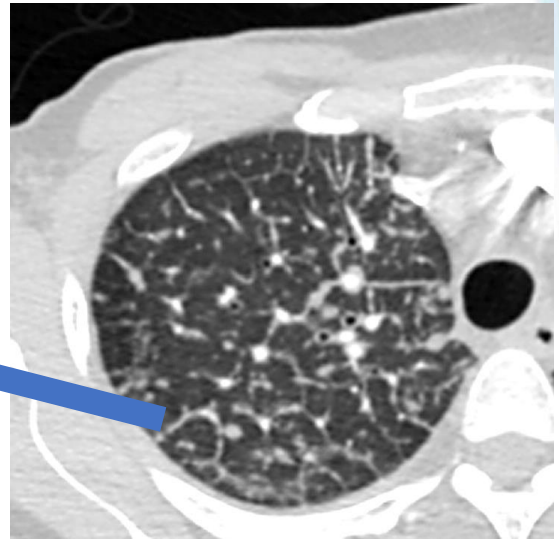

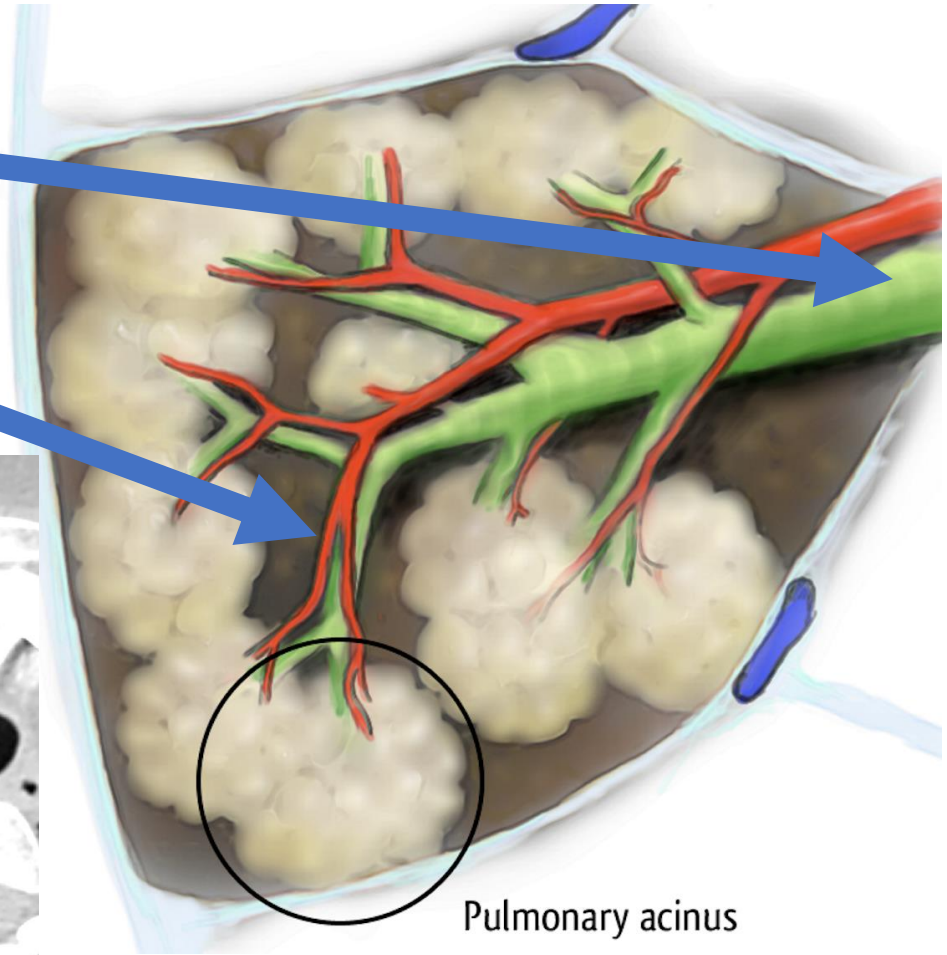

#Beispiele

Lobärpneumonie

Bronchopneumonie

Interstitielle Pneumonie

Lungenödem

Lungengerüst

Pleura

Atelektase

Tumor

Lobärpneumonie

- Pneumokokken
- Klebsiella
- Legionella
- Hämophilus
- Tuberkulose

Lobärpneumonie

„Zusamenhängende Transparenzminderung“

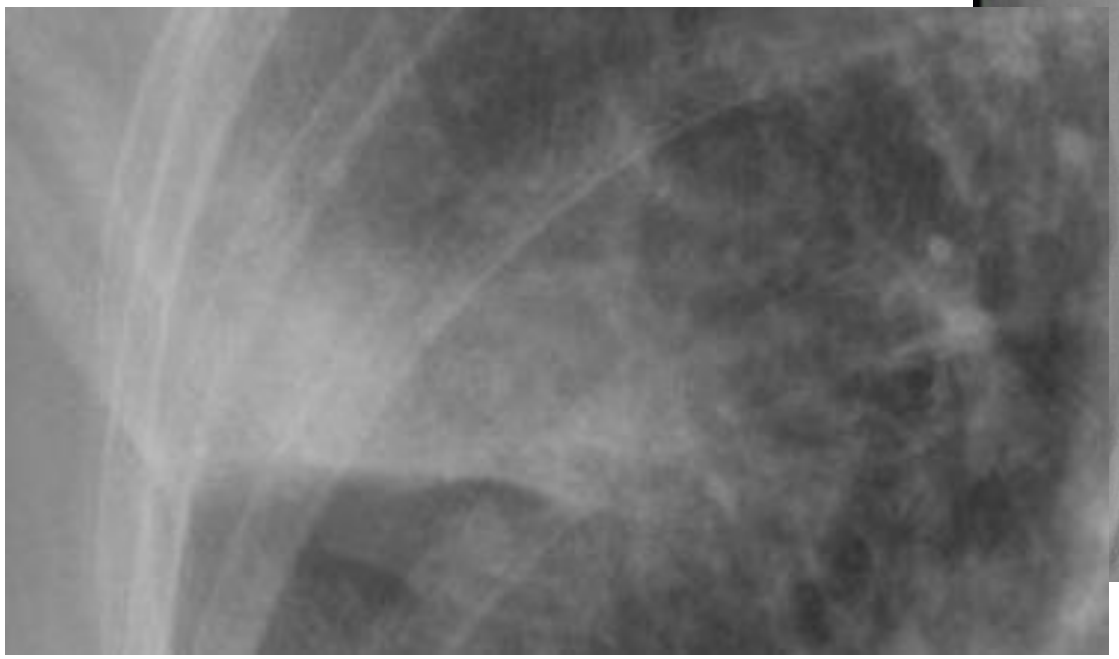

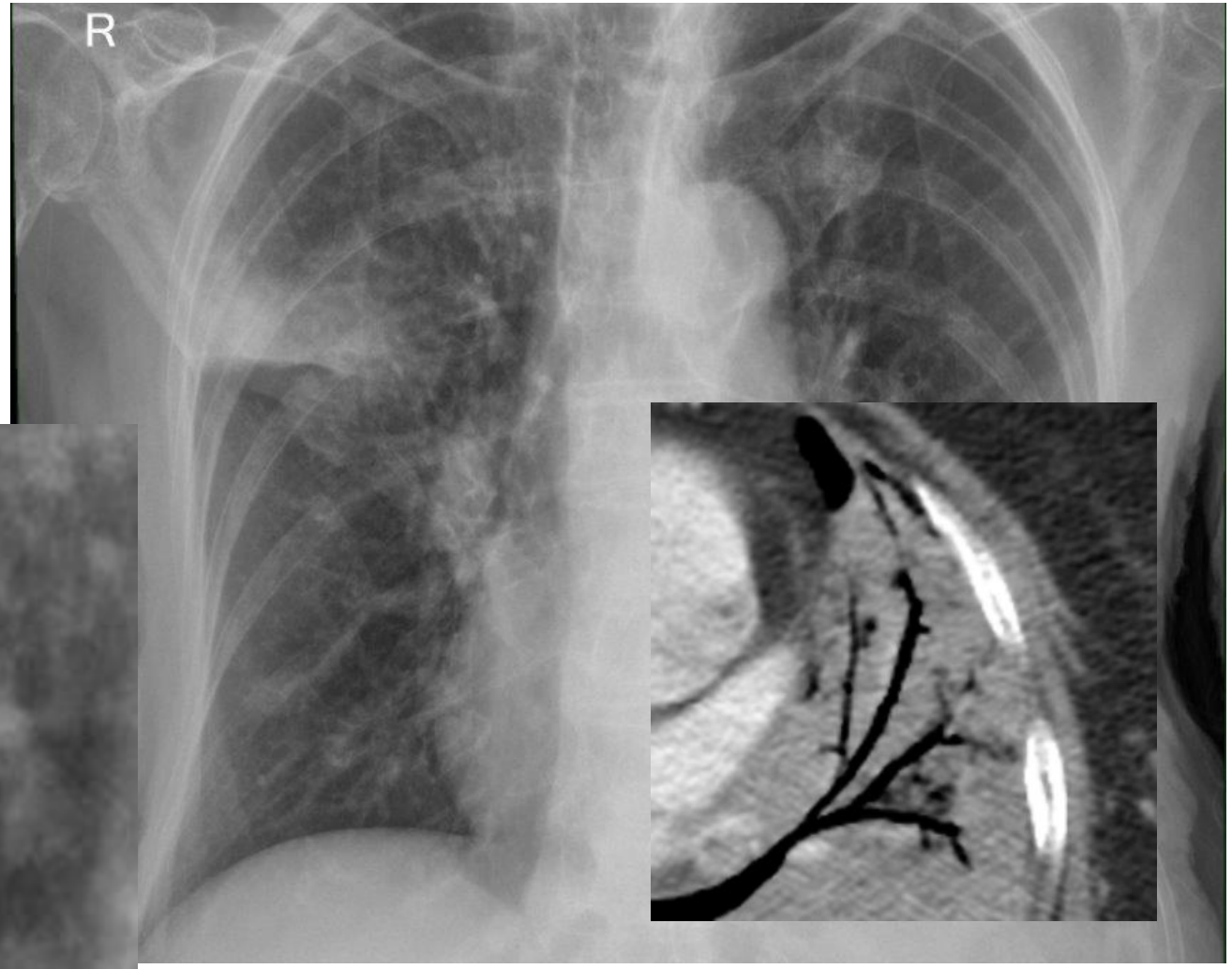

Lobärpneumonie

Distal der Bronchioli respiratorii

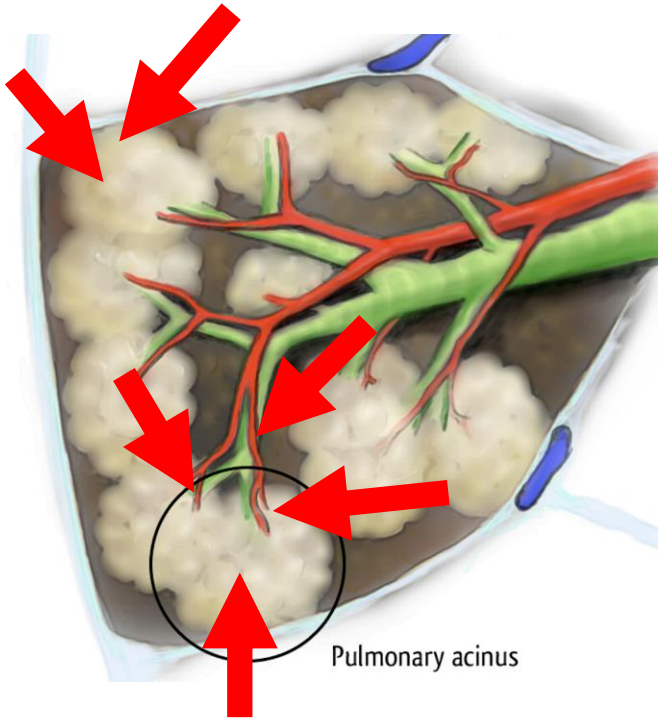

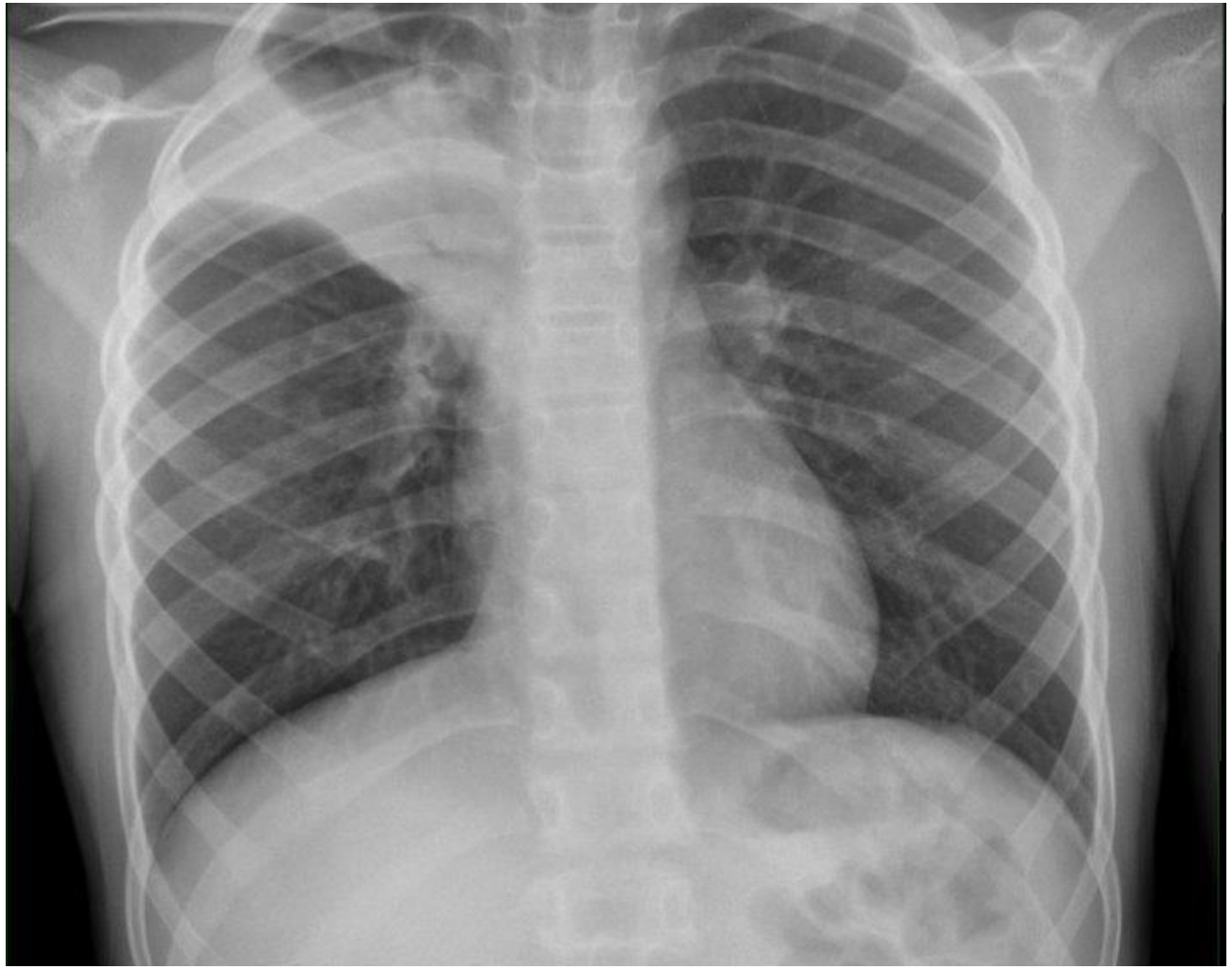

Lobärpneumonie

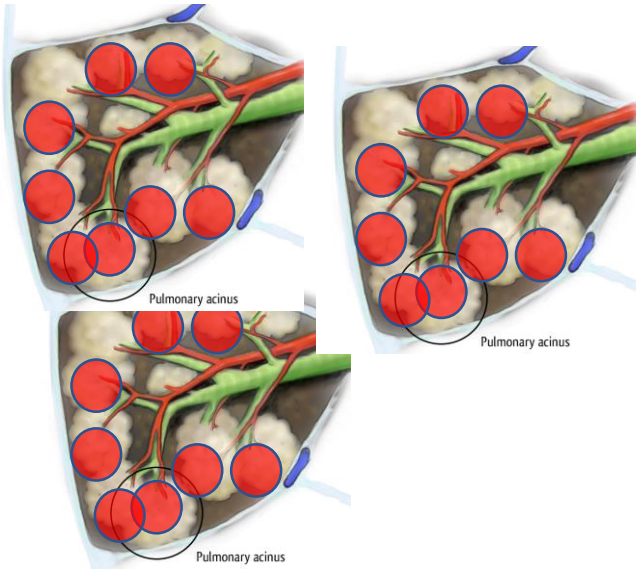

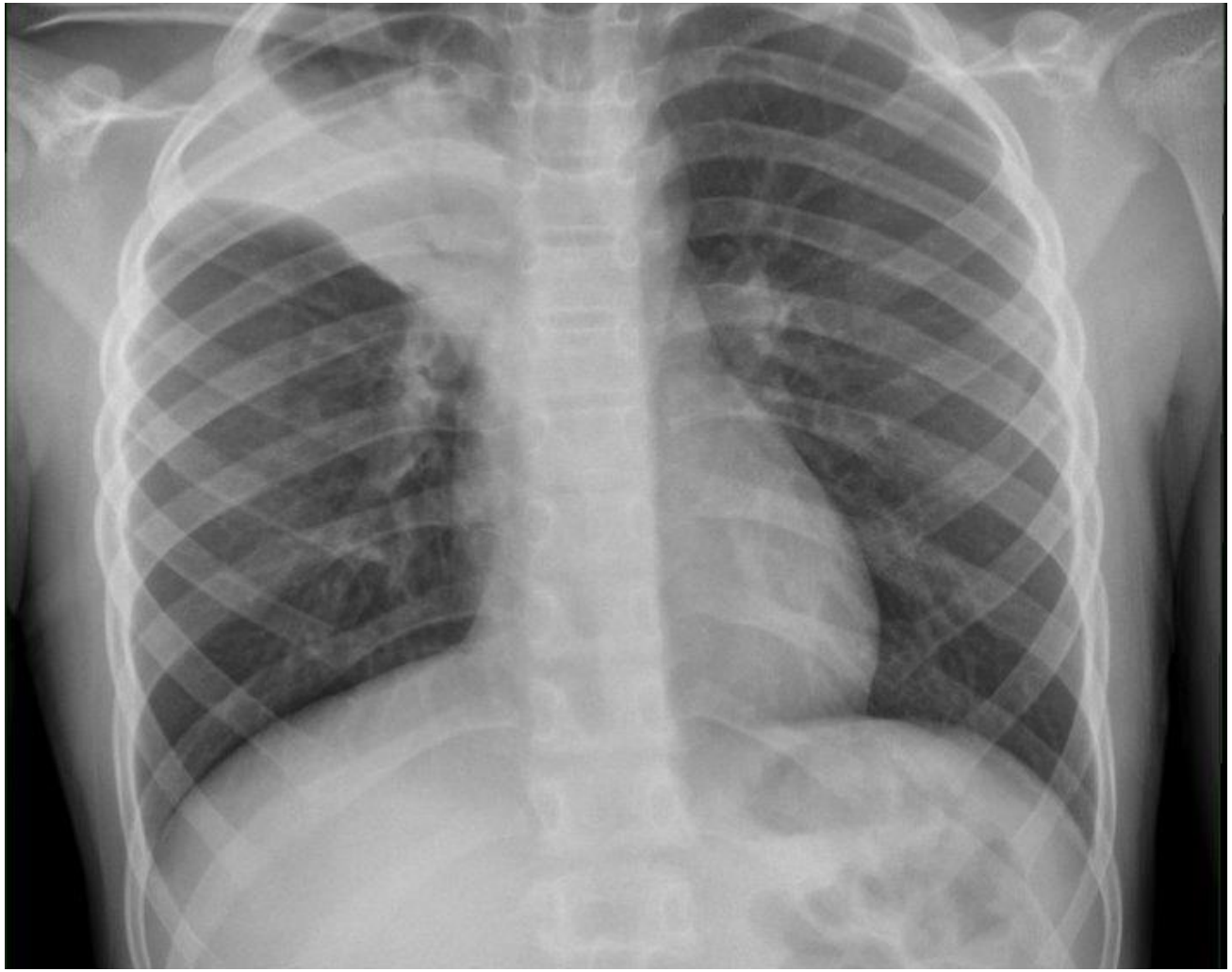

Lobärpneumonie

Distal der Bronchioli respiratorii

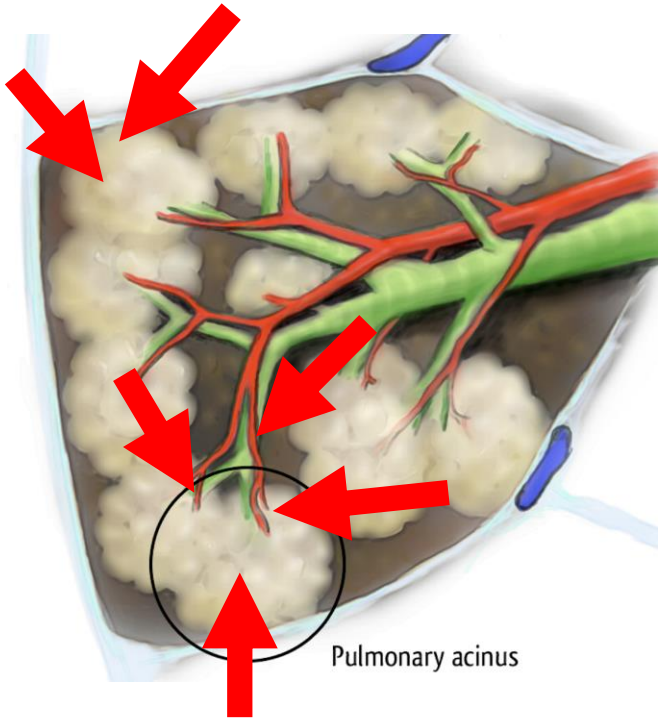

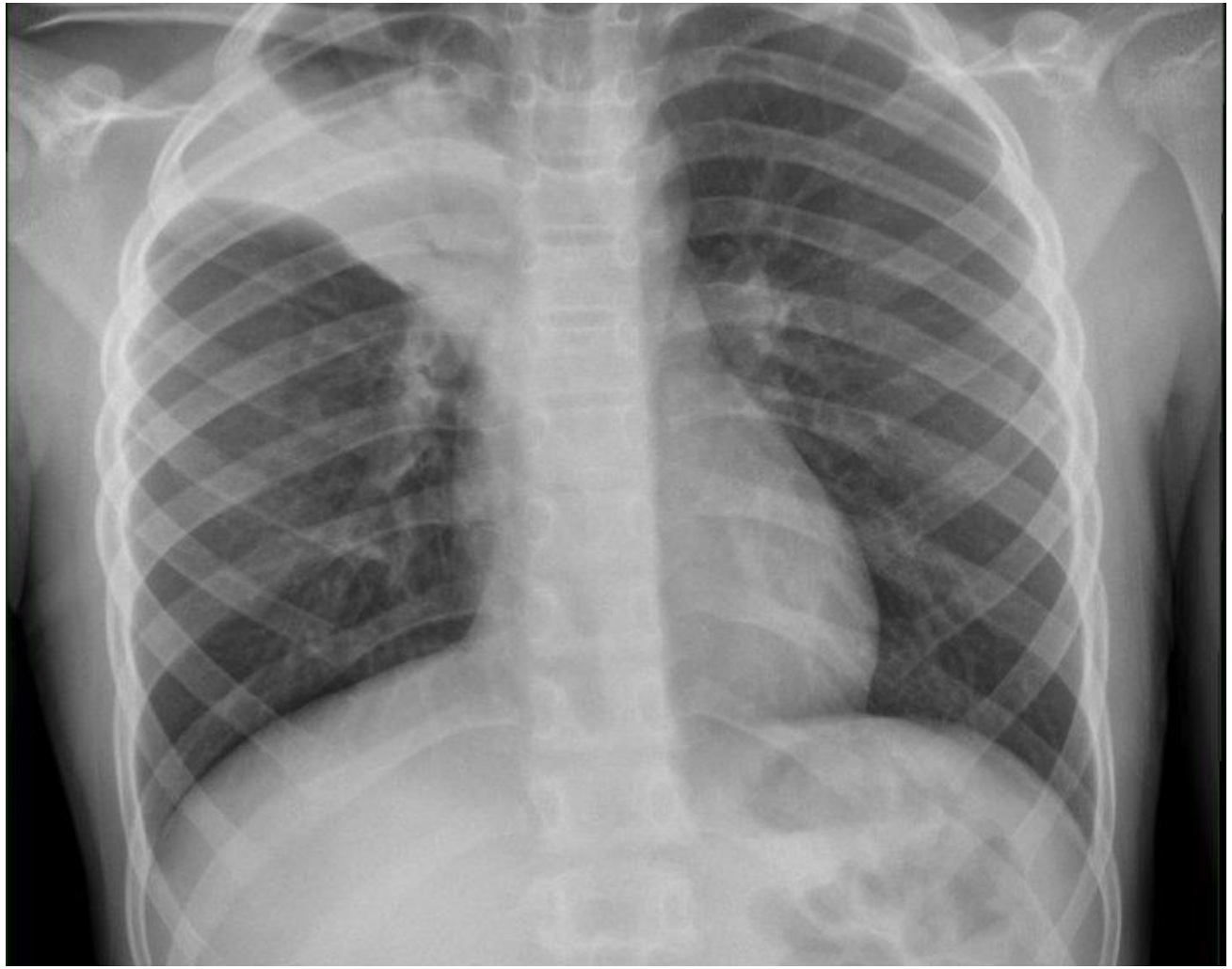

Bronchpneumonie

Klebsiella

Hämopphilus

Pseudomonas

E coli

Proteus

Staph aureus meist hämatogen

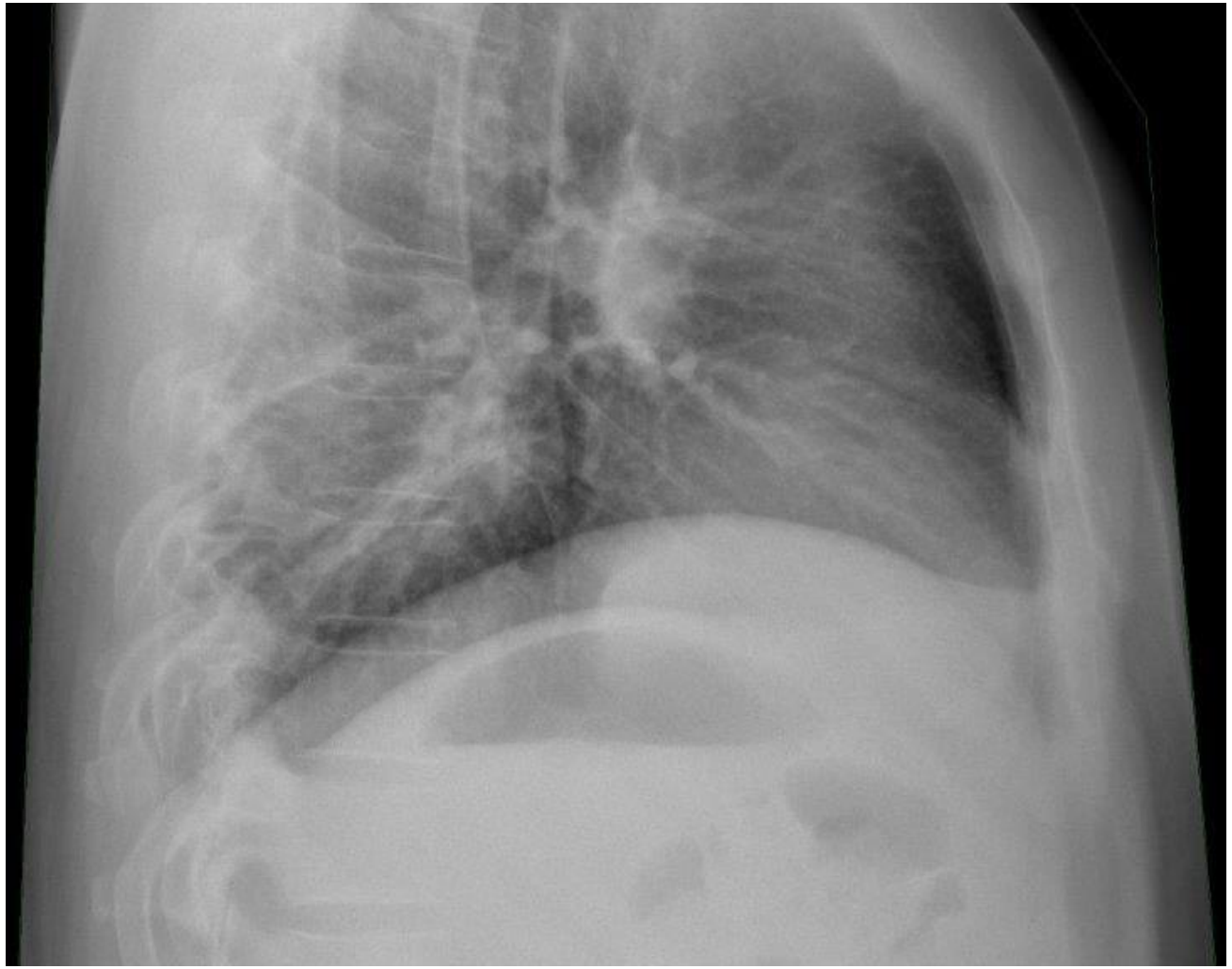

Bronchpneumonie

Lobus Venae Azygos

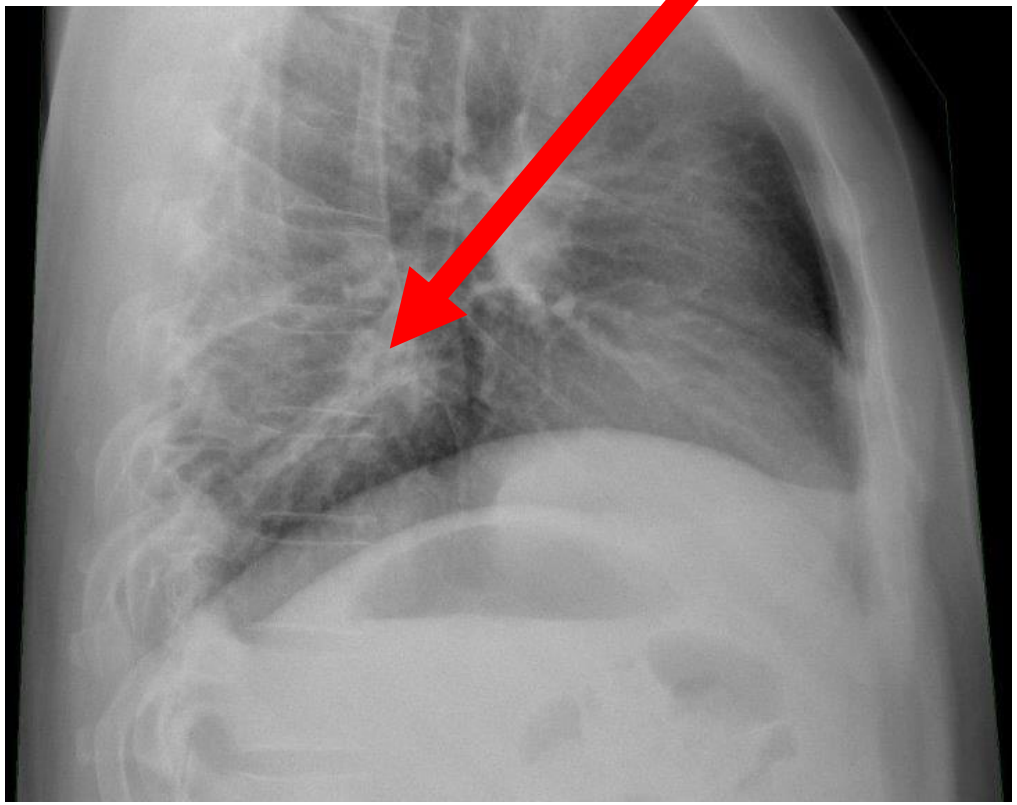

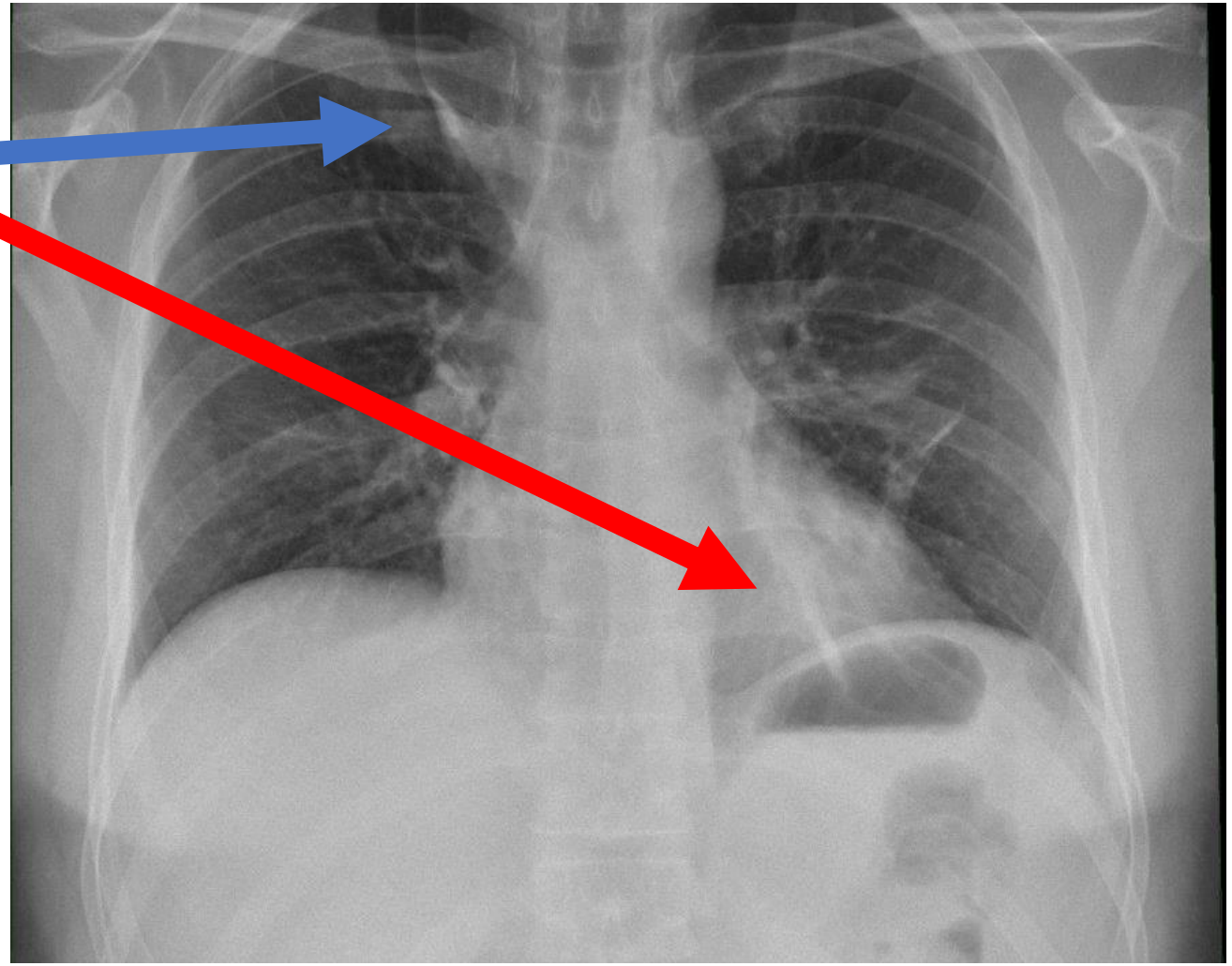

Lobus venae Azygos

Bronchpneumonie

- Bronchioli terminales

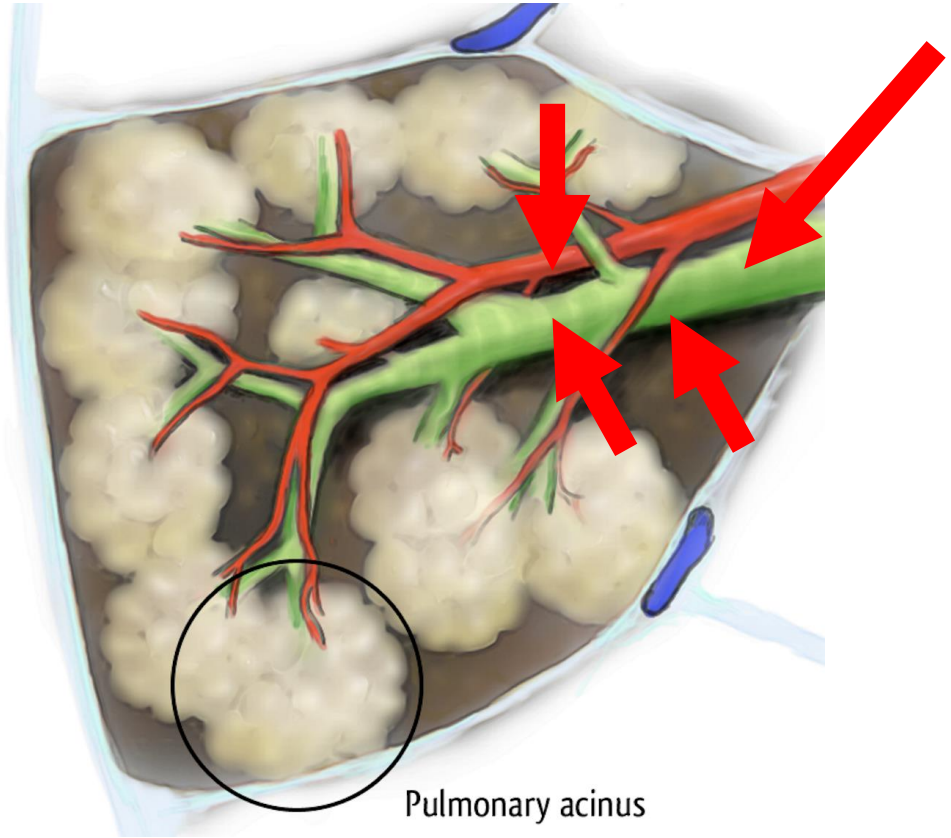

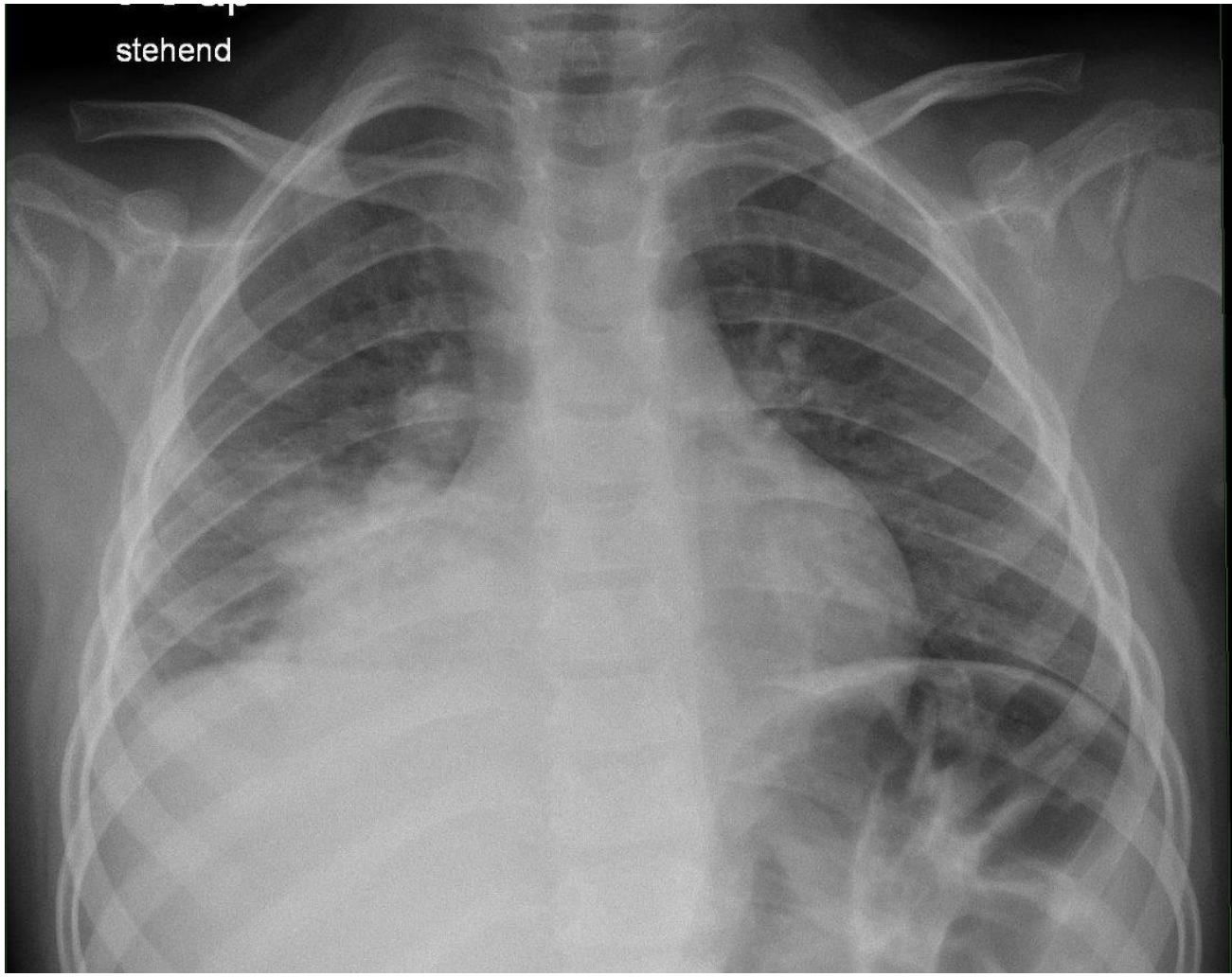

Bronchpneumonie

- Bronchioli terminales

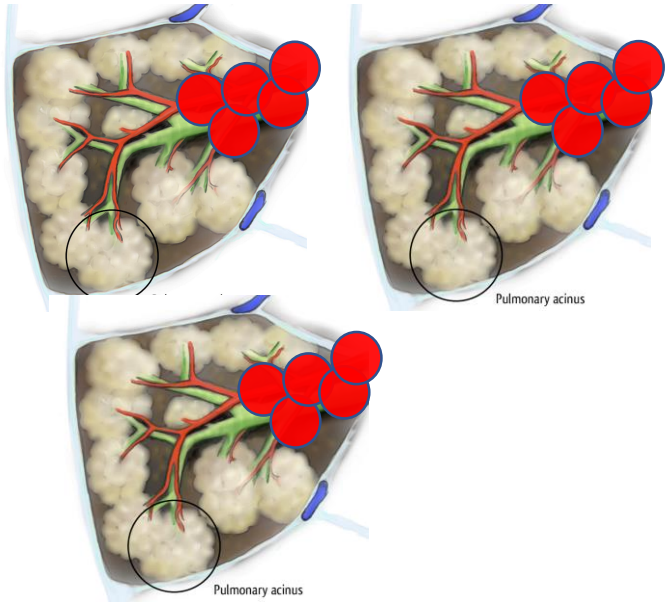

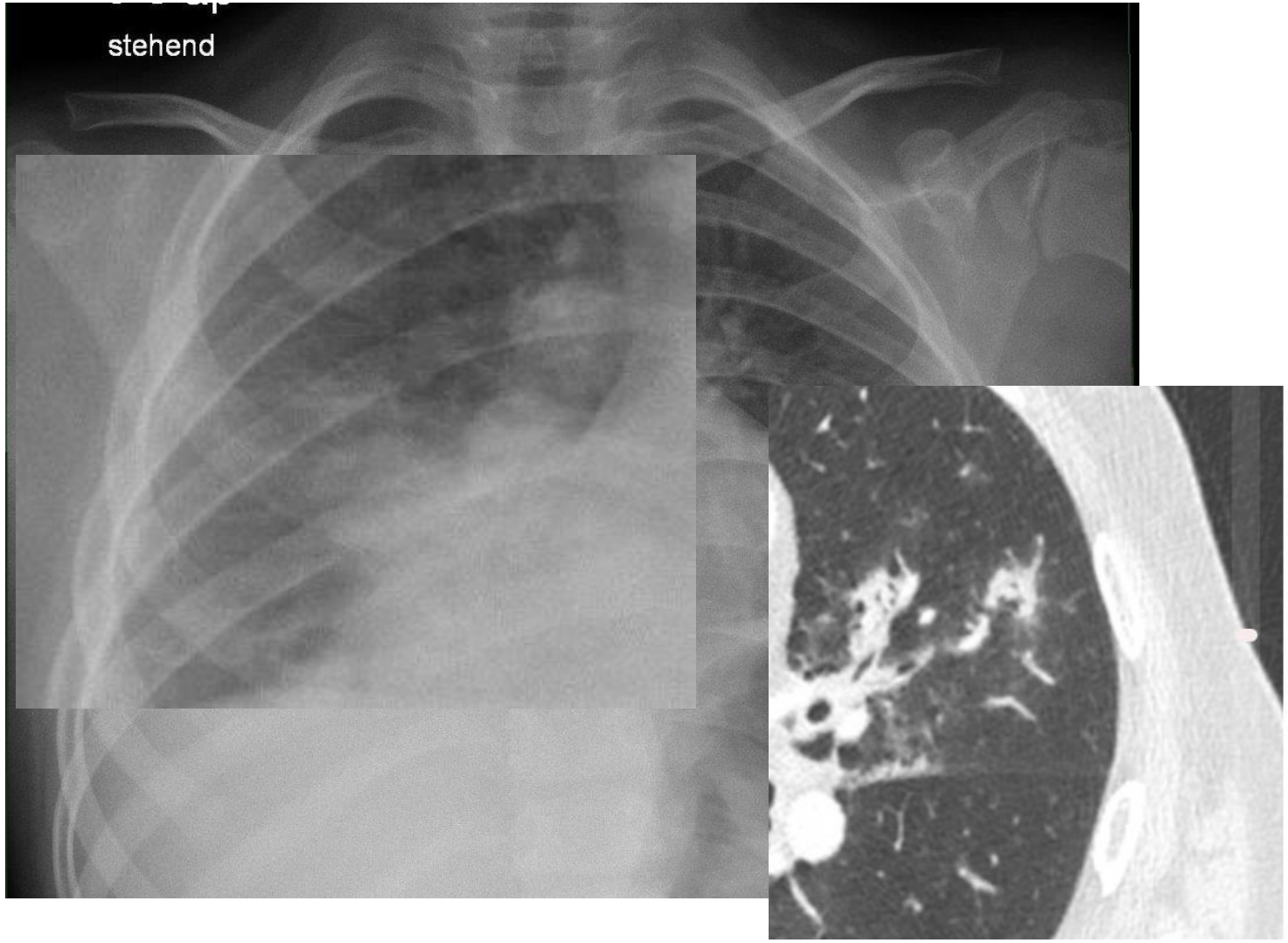

Bronchpneumonie

Konfluierende azinäre „Flecken“

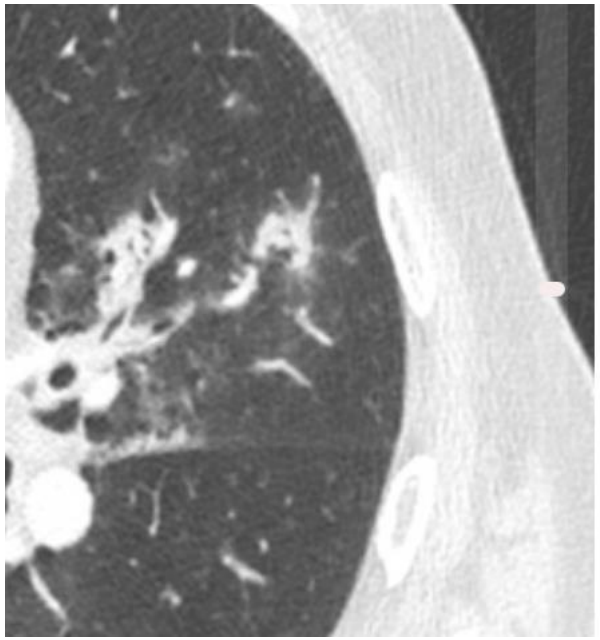

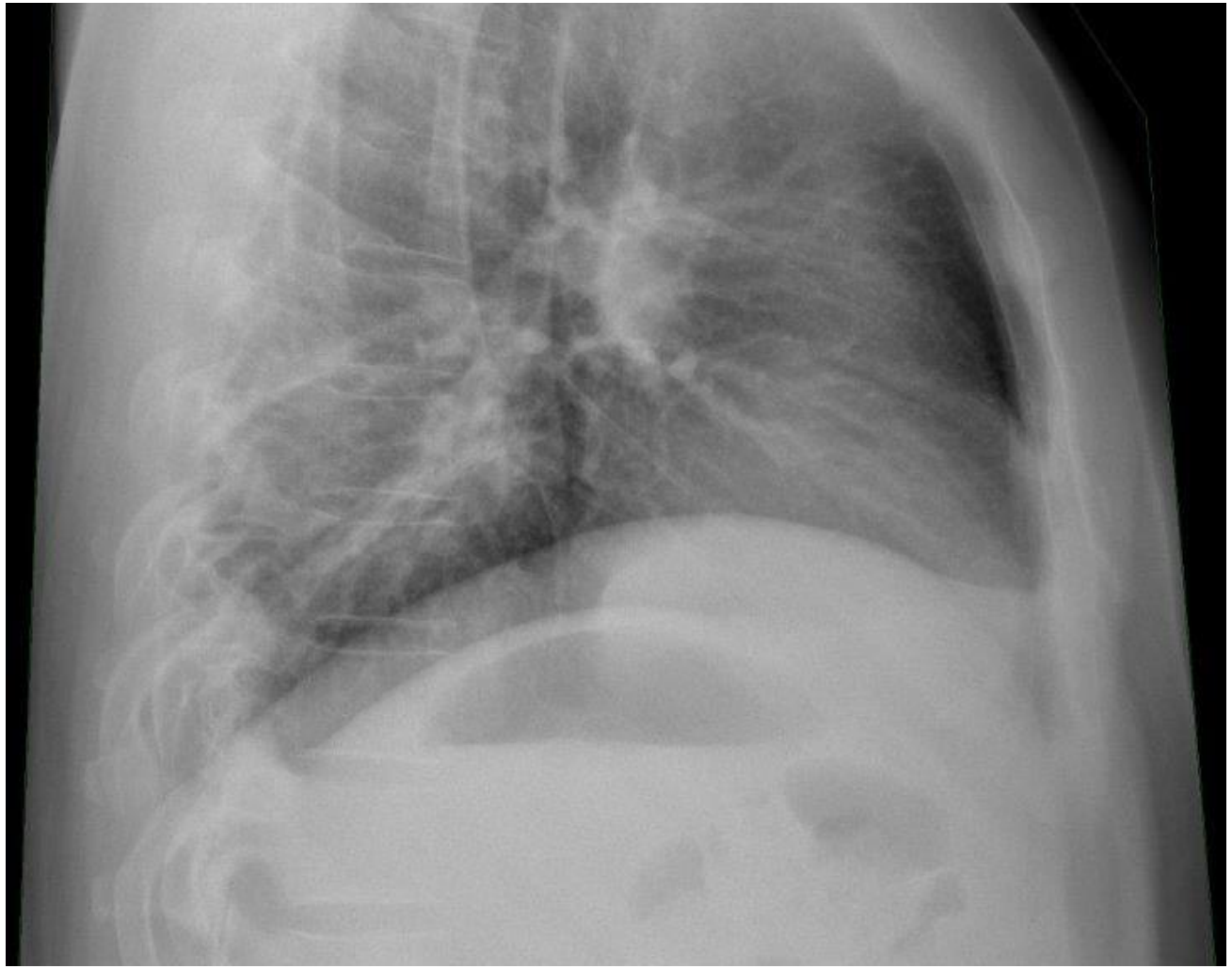

Bronchpneumonie

Klebsiella

Hämopphilus

Pseudomonas

E coli

Proteus

Staph aureus meist hämatogen

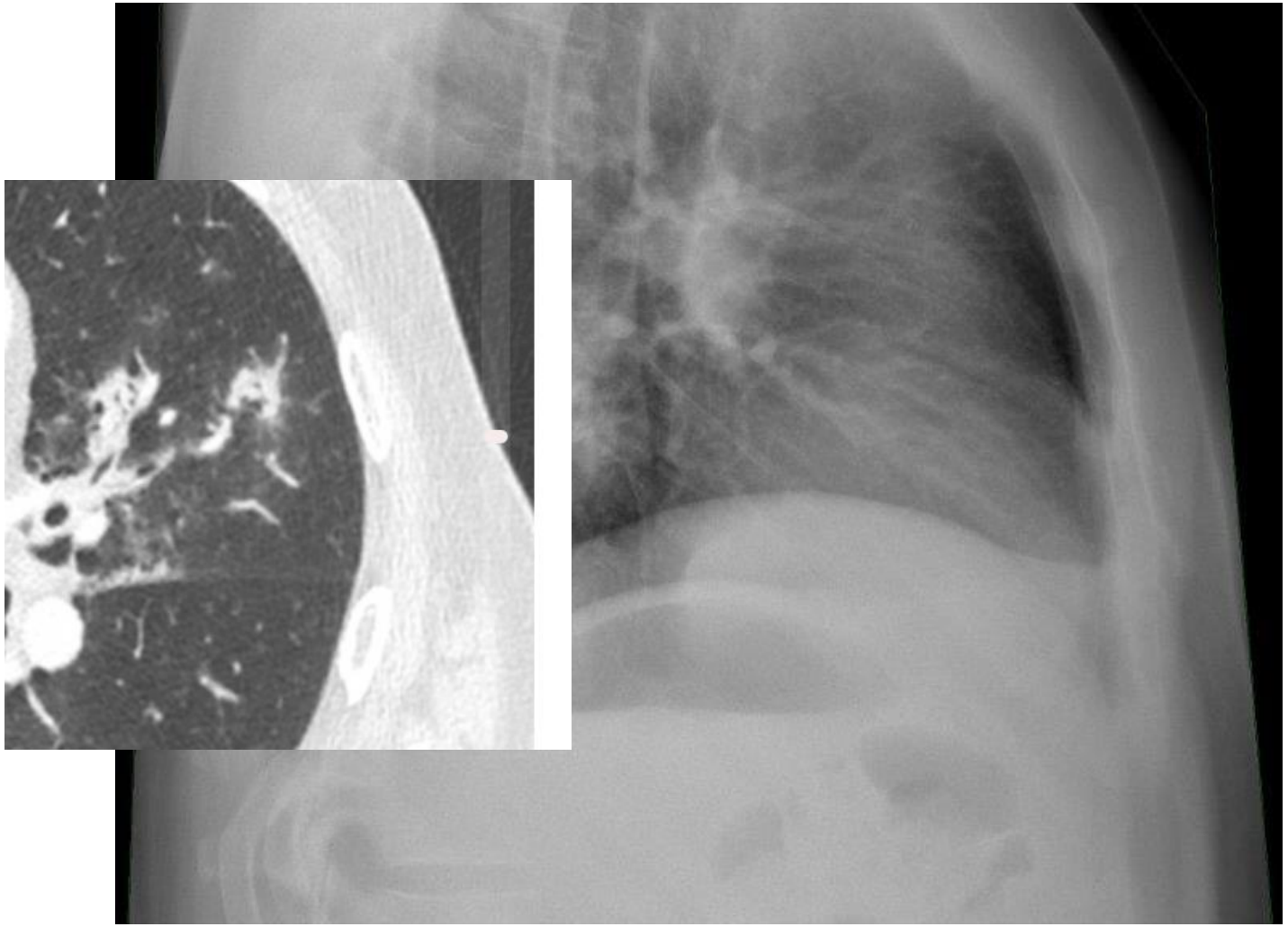

Bronchopneumonie

Pleuraerguß Exsudat Fibrinfäden

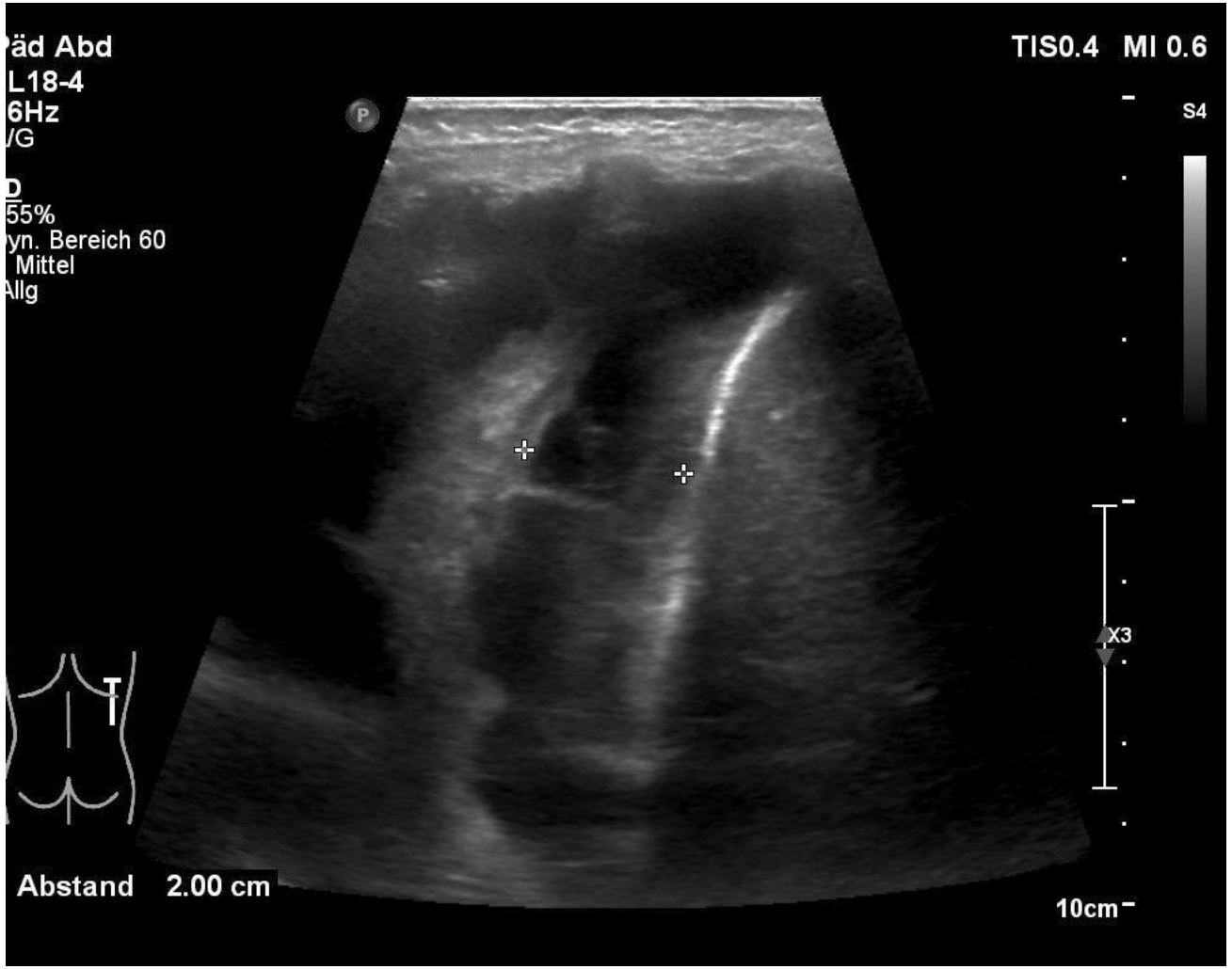

Interstitielle Lungenerkrankung „Pneumonie“

Rauchen

Organische und anorganische inhal. Noxen

Gase und Dämpfe

Medikamente

Strahlung

Infektion

Indiopathisch(e)

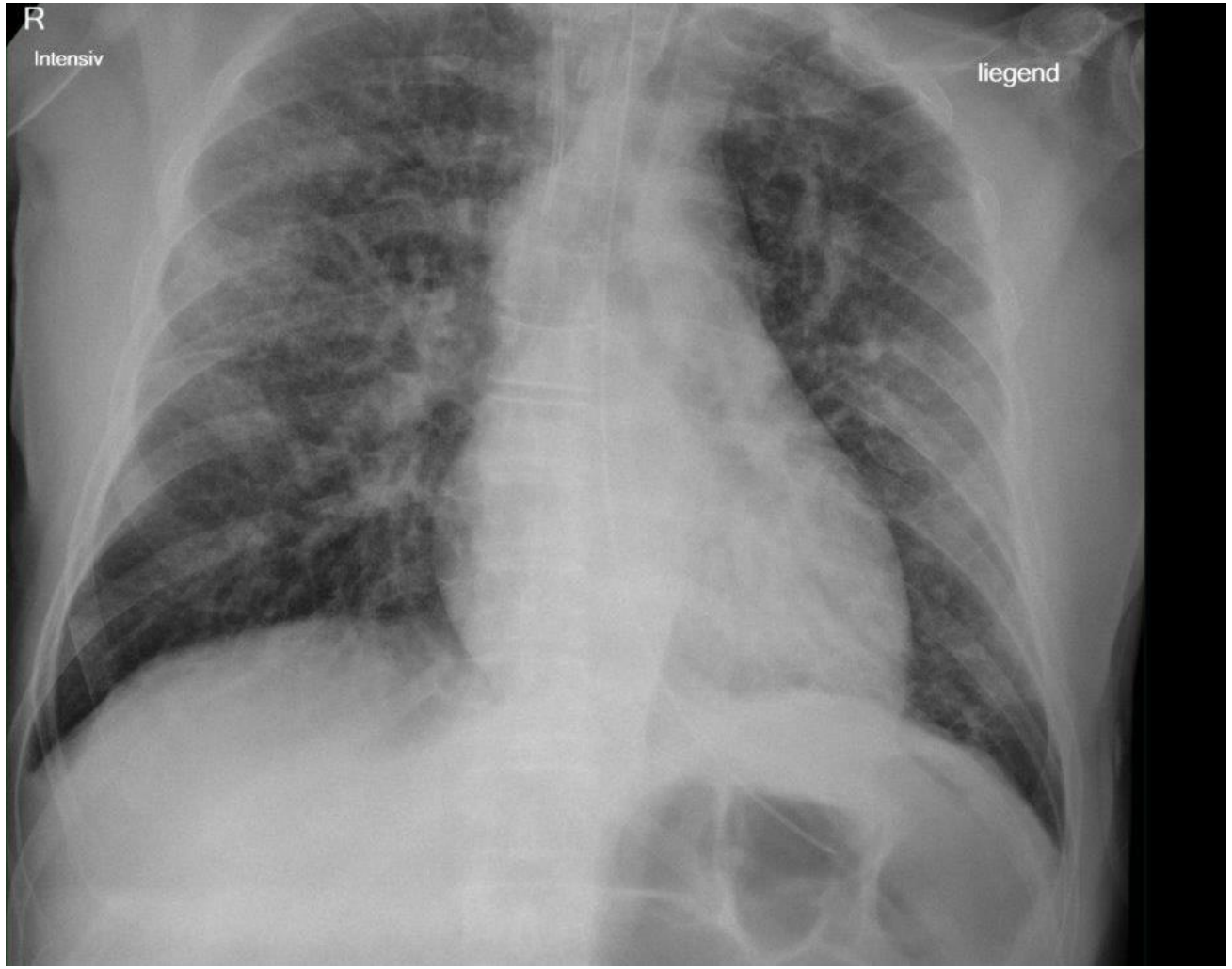

Interstitielle Pneumonie

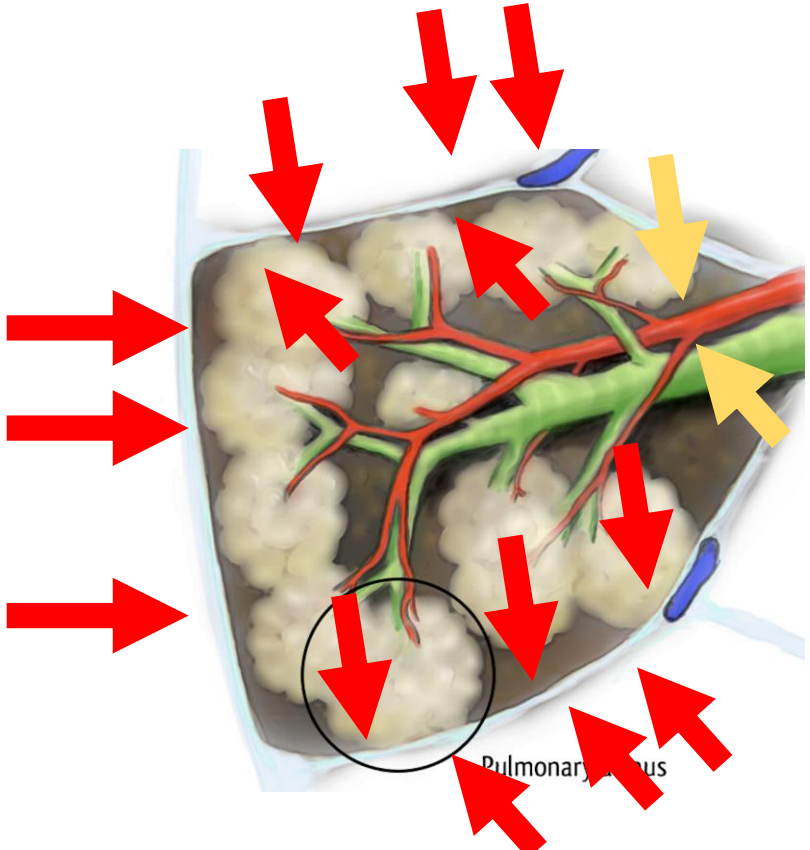

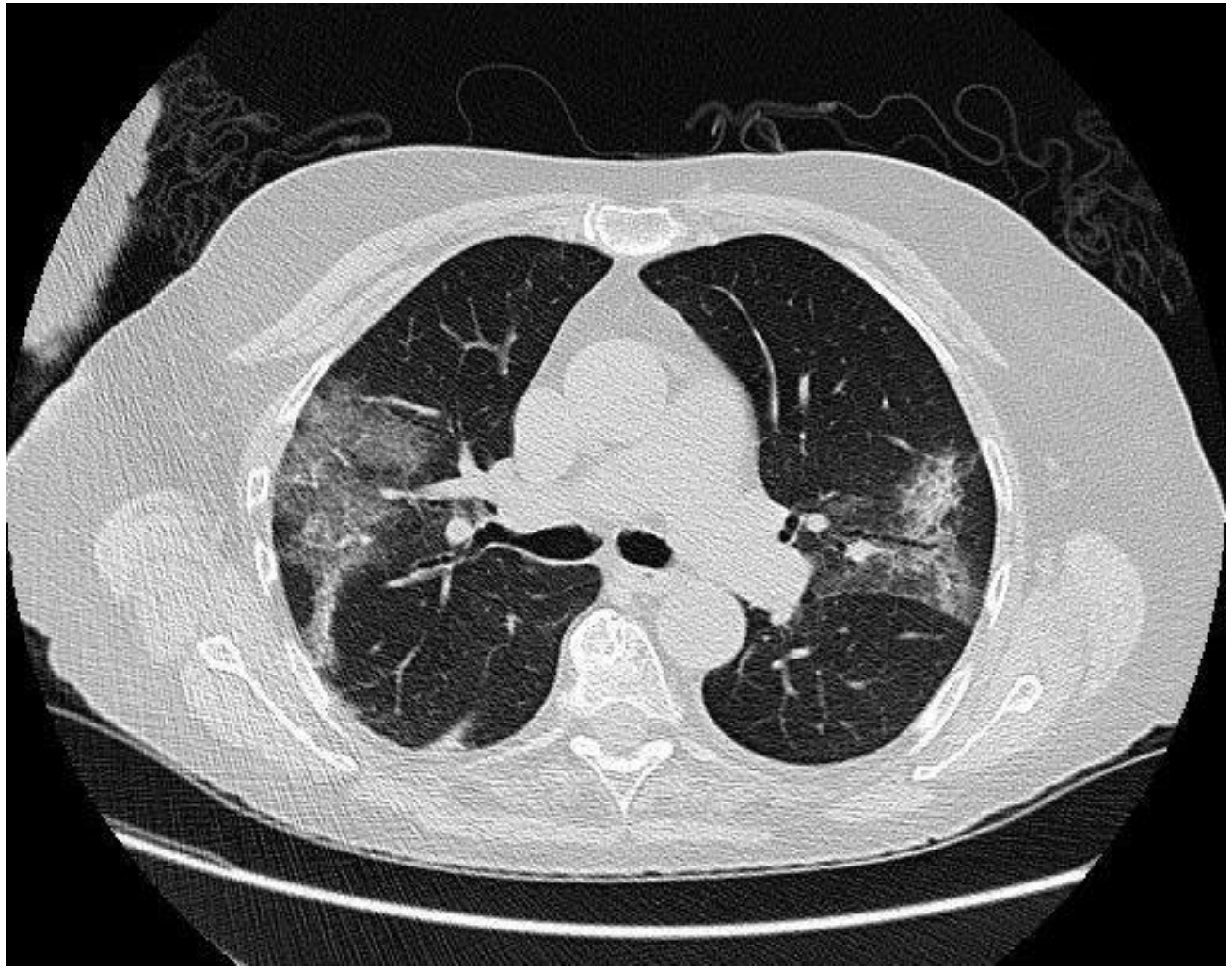

Interstitielle Pneumonie

Covid-19

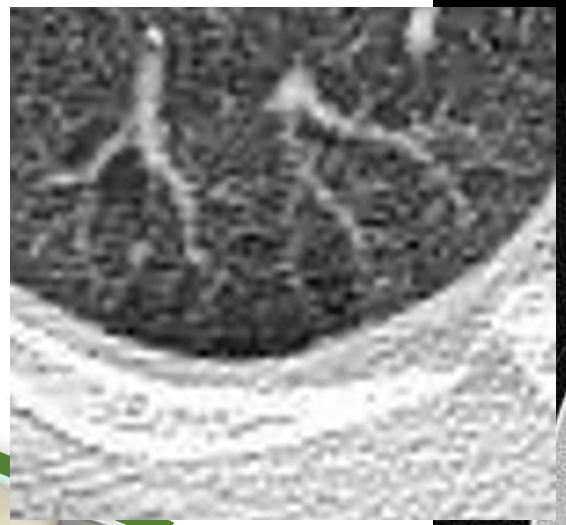

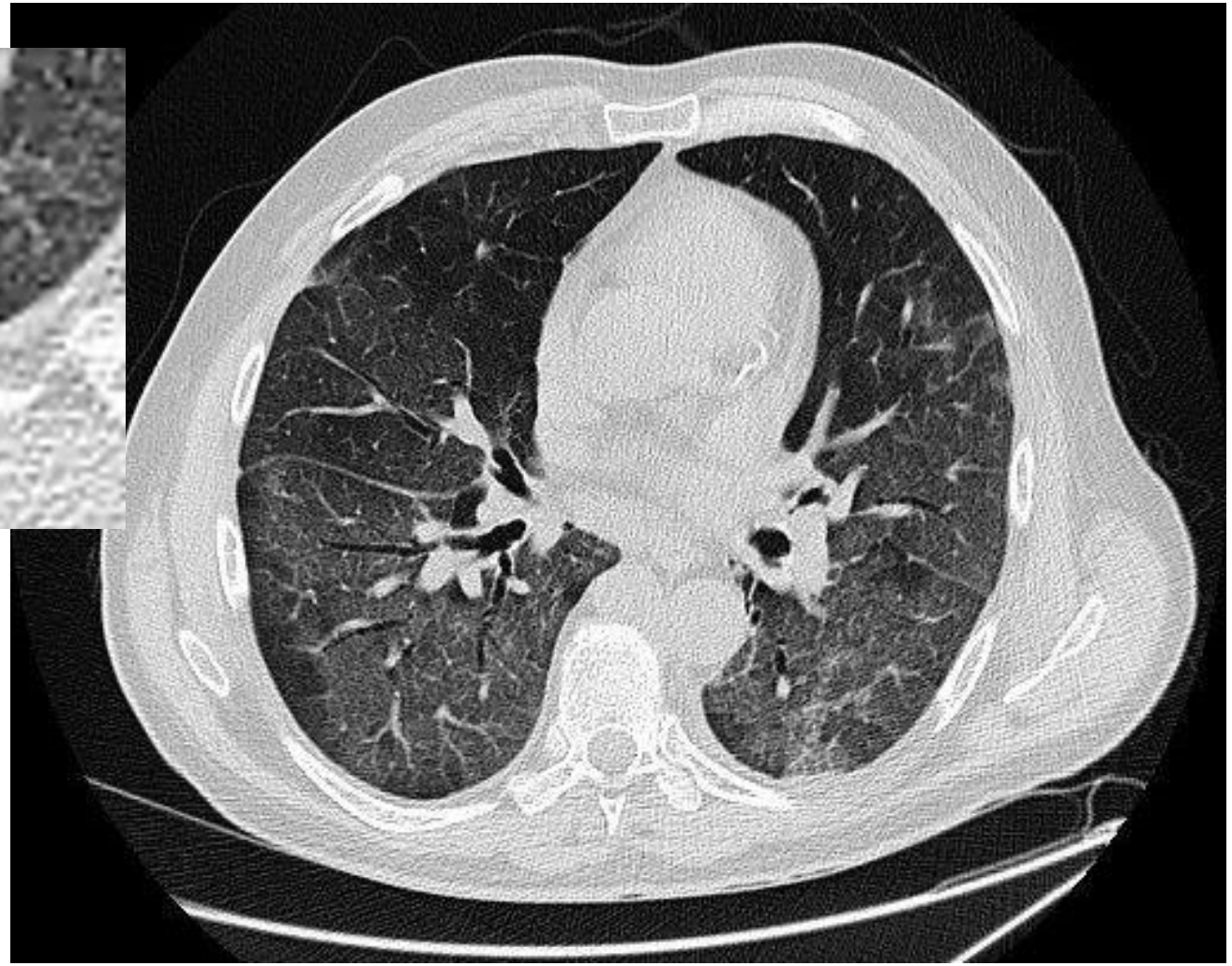

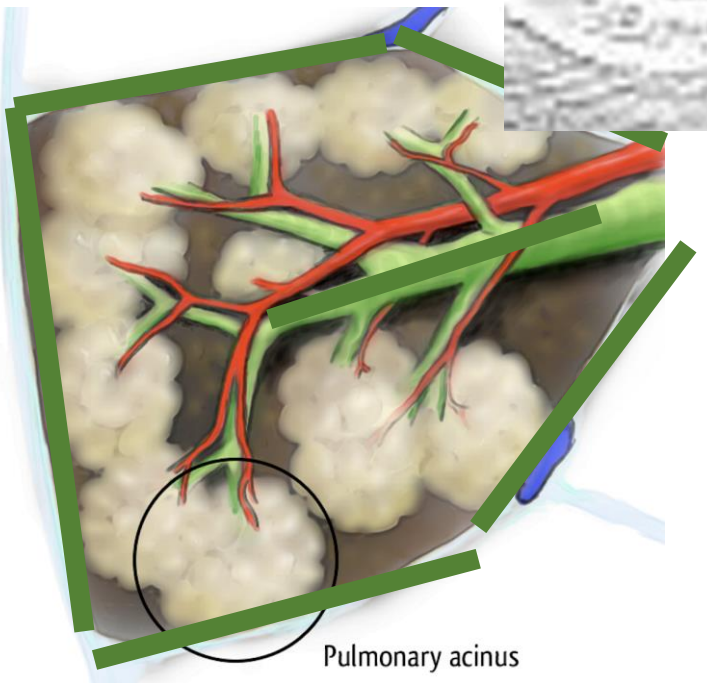

Interstitielle Pneumonie

Covid-19

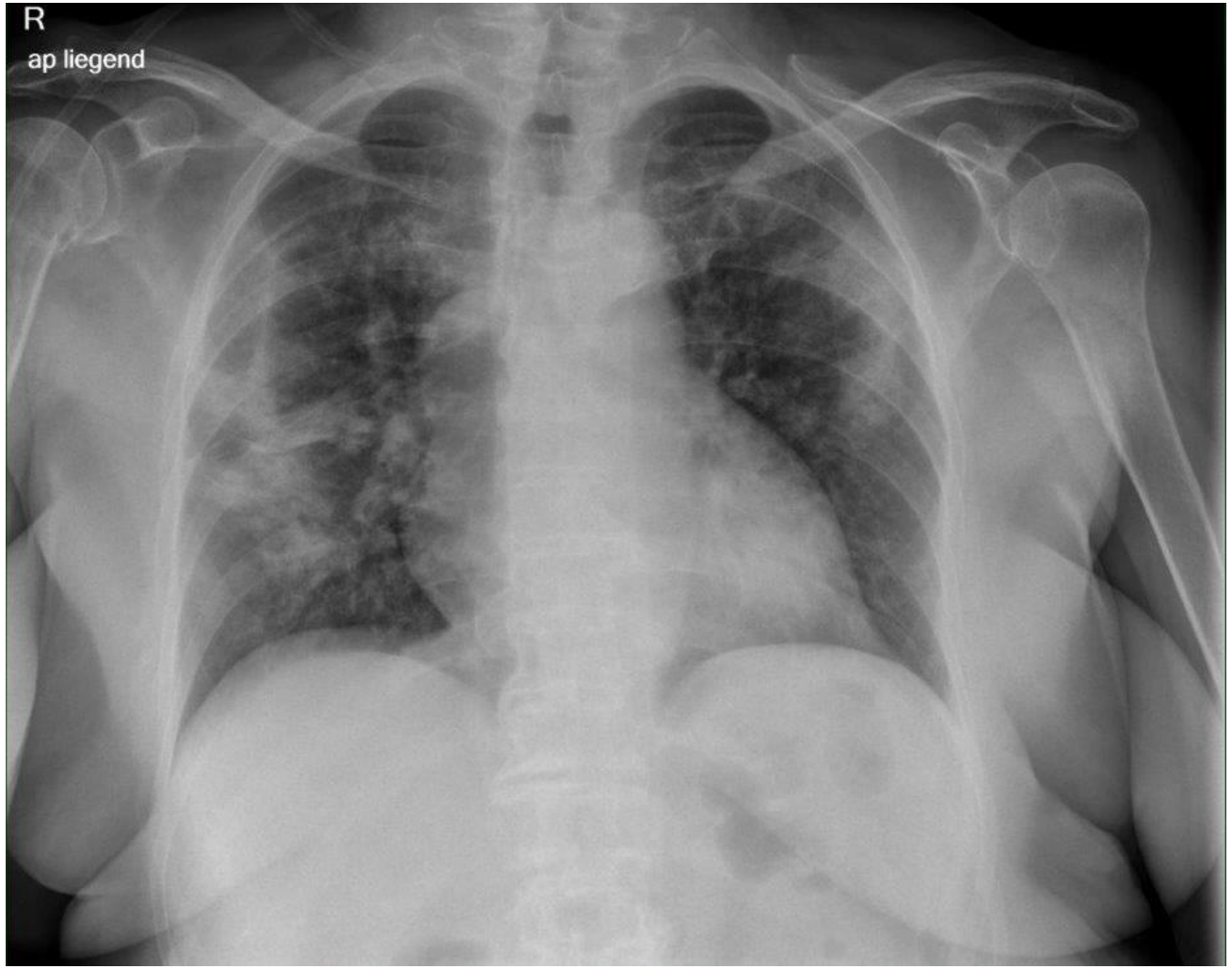

Interstitielle Pneumonie

Covid-19

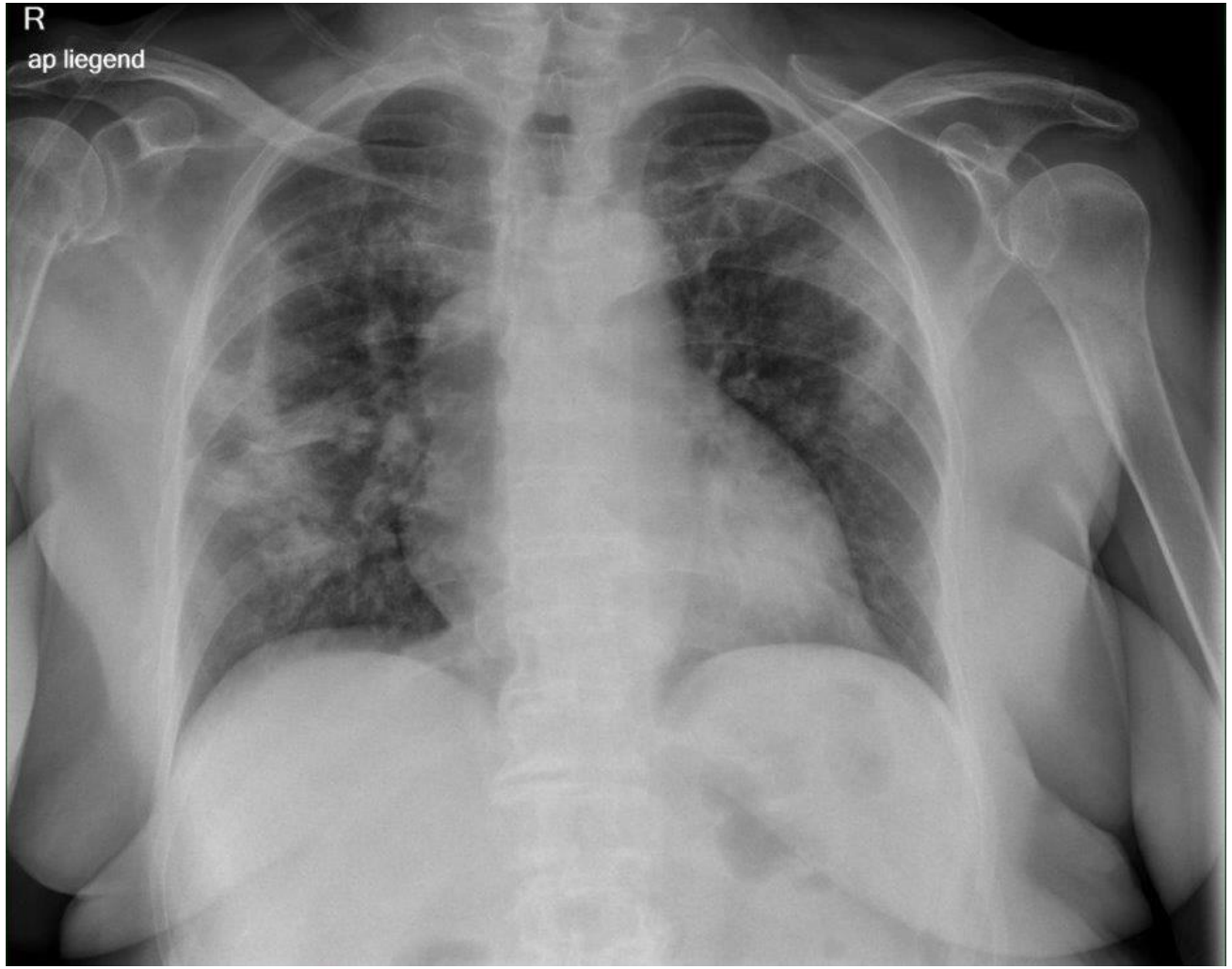

Interstitielle Pneumonie

Covid-19

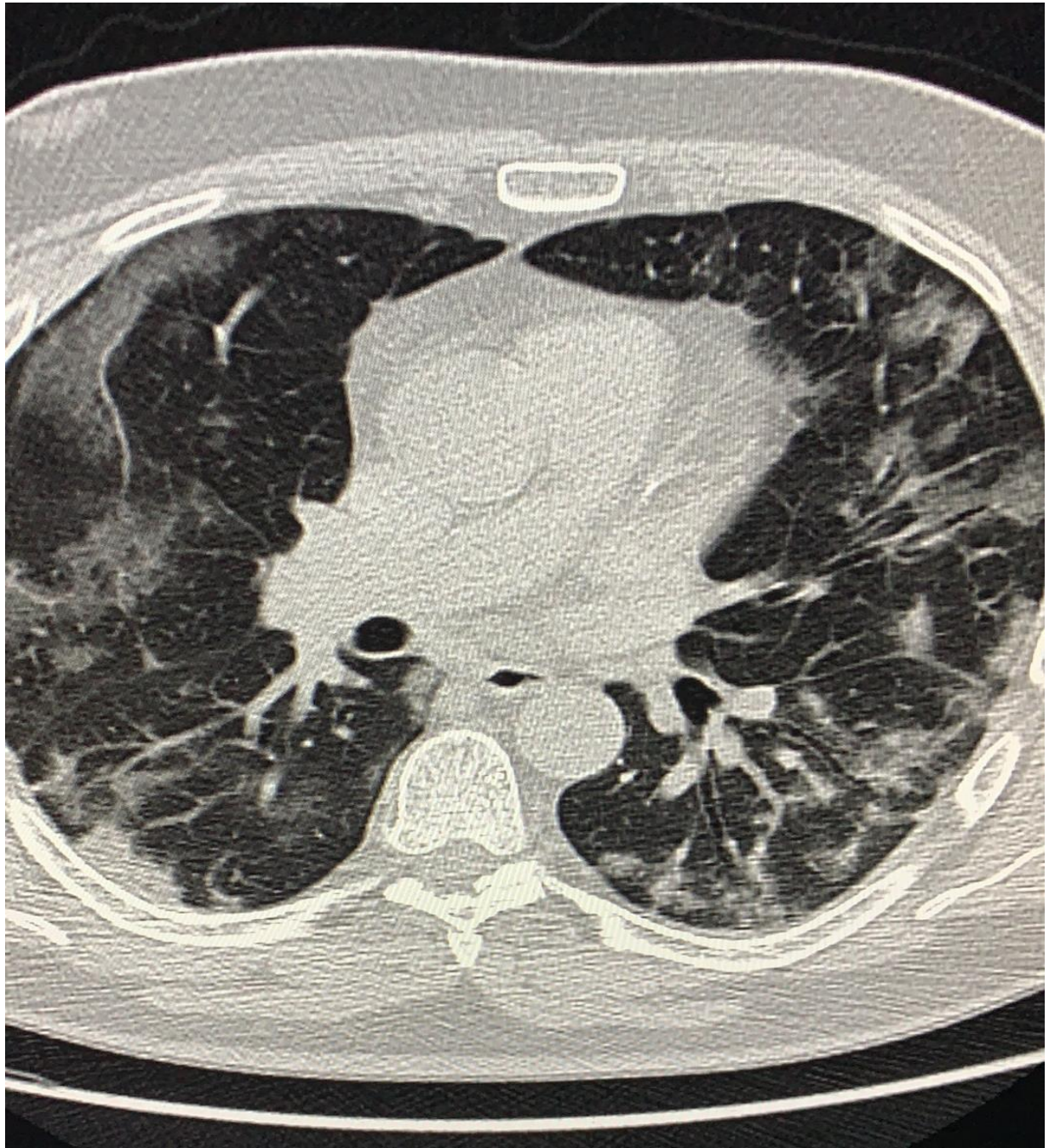

Interstitielle Pneumonie

Atoll sign

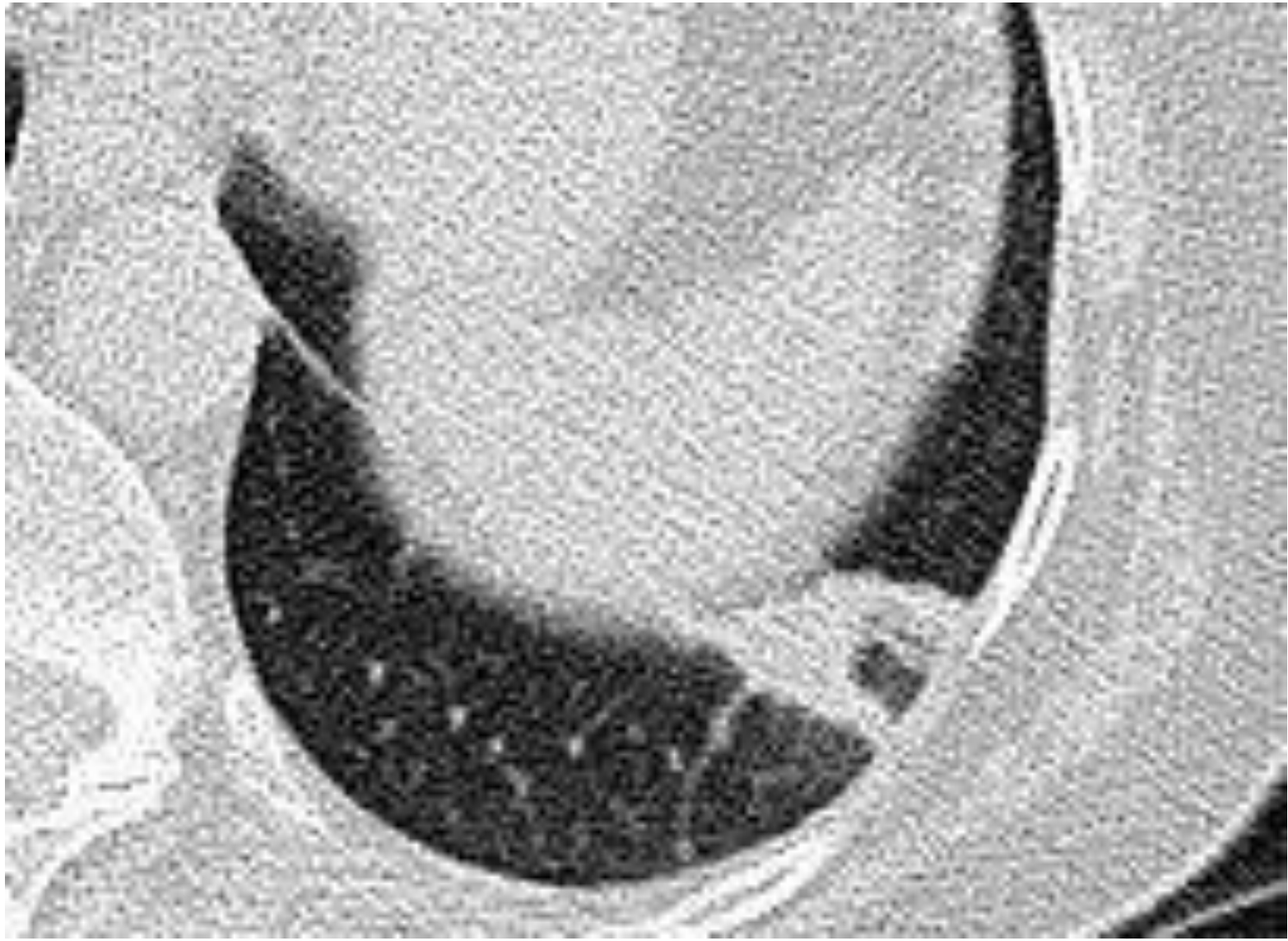

Interstitielle Pneumonie

Atoll sign oder reversed Halo sign

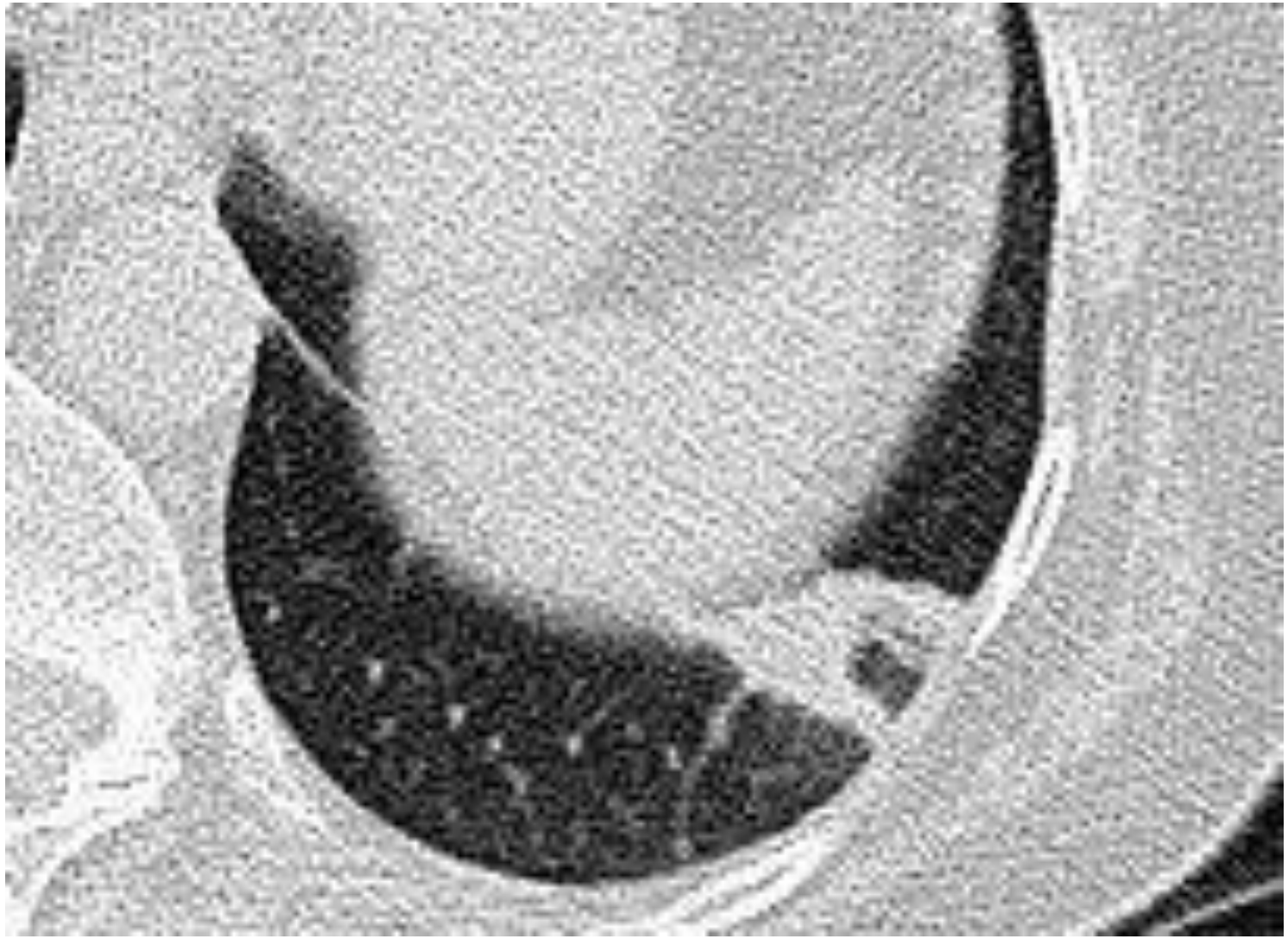

Interstitielles Ödem

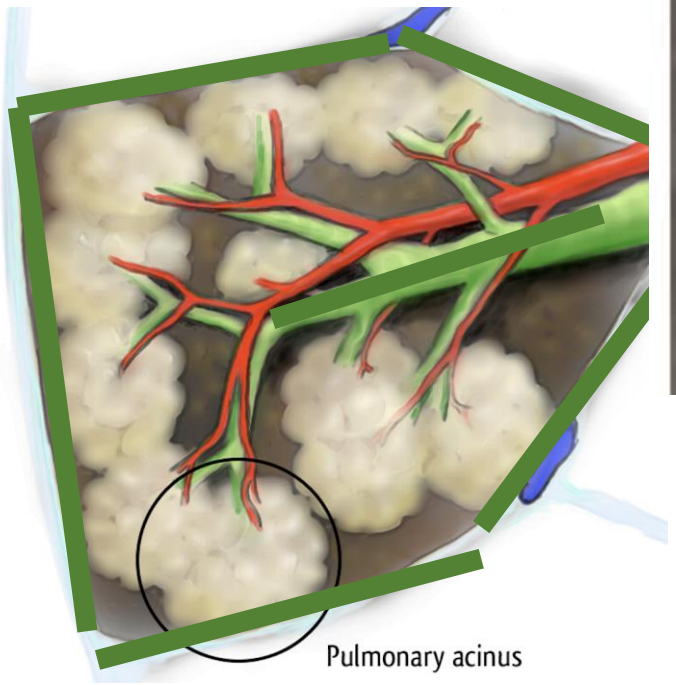

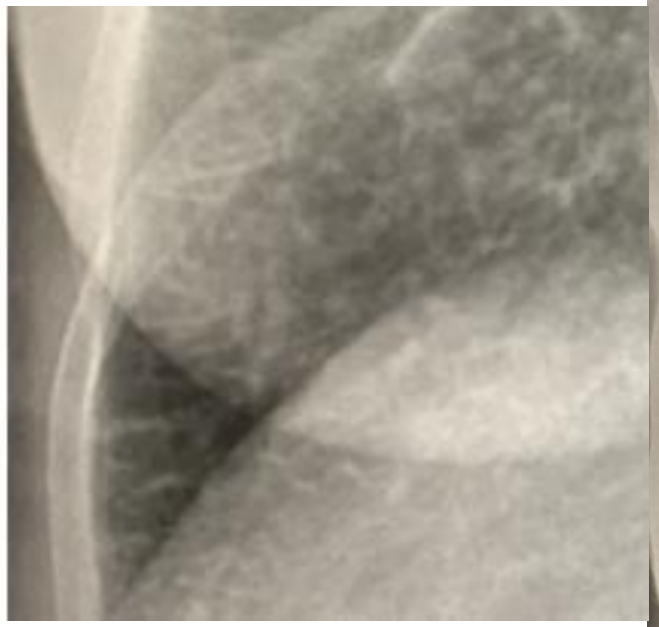

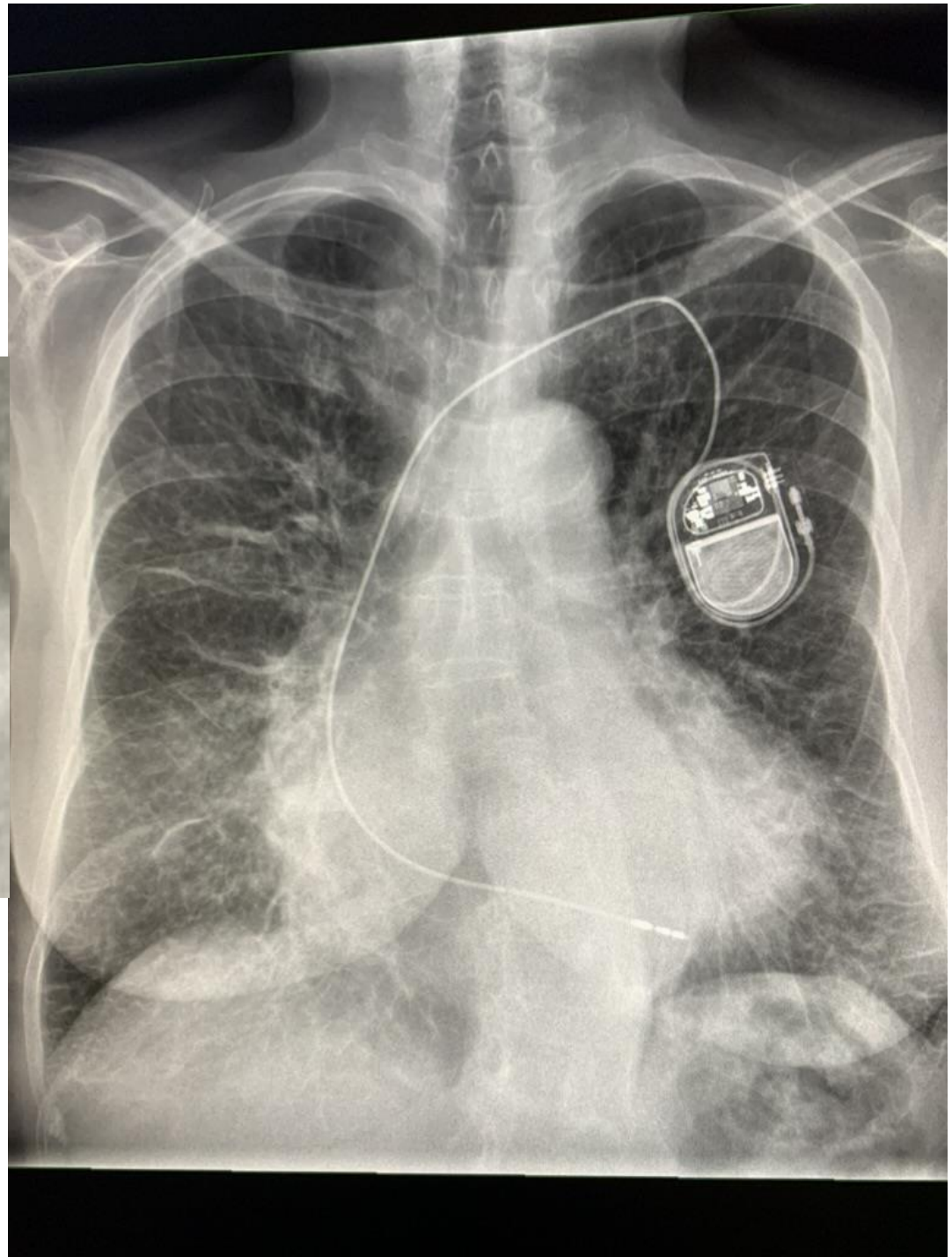

Interstitielles Ödem

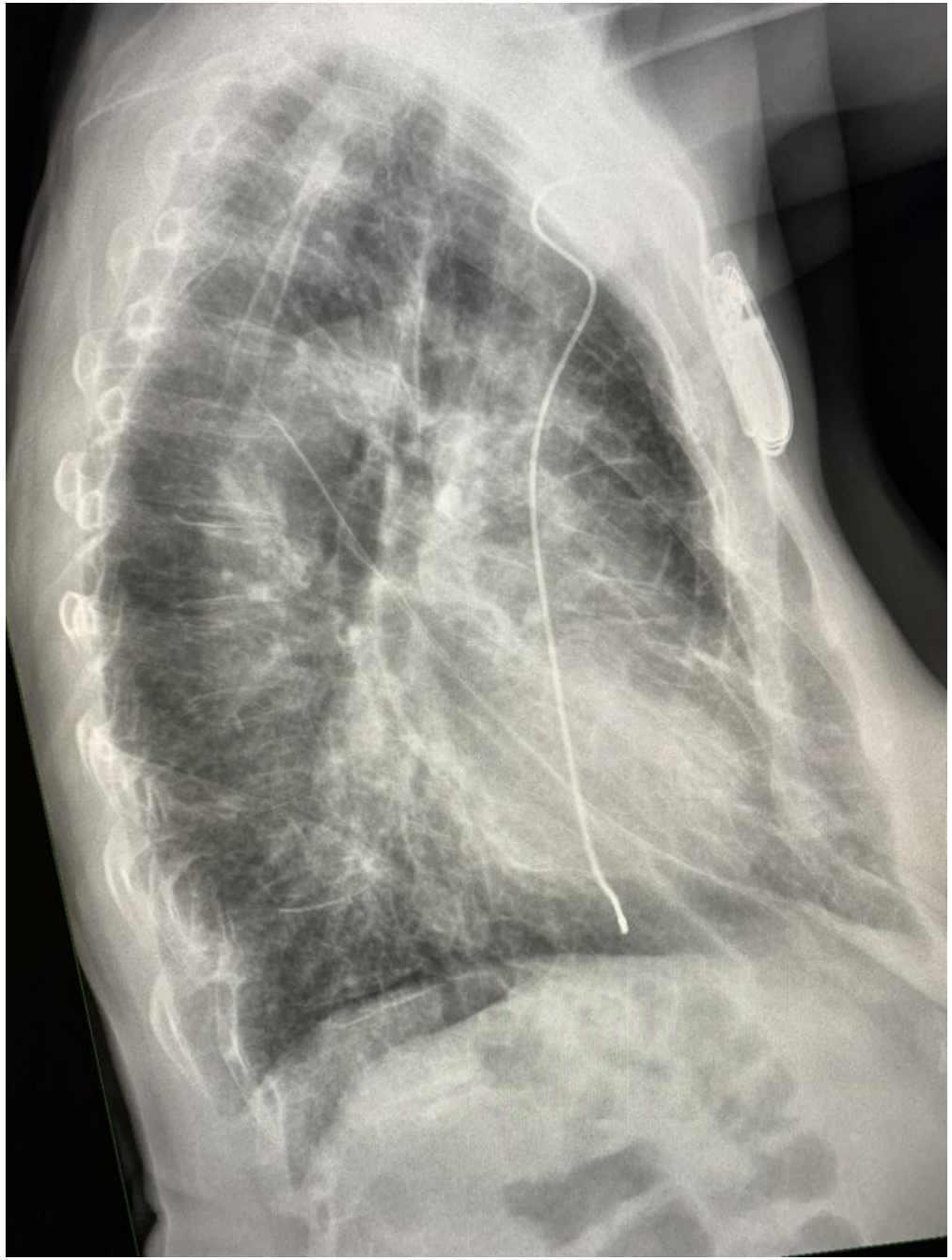

Linksdekomp

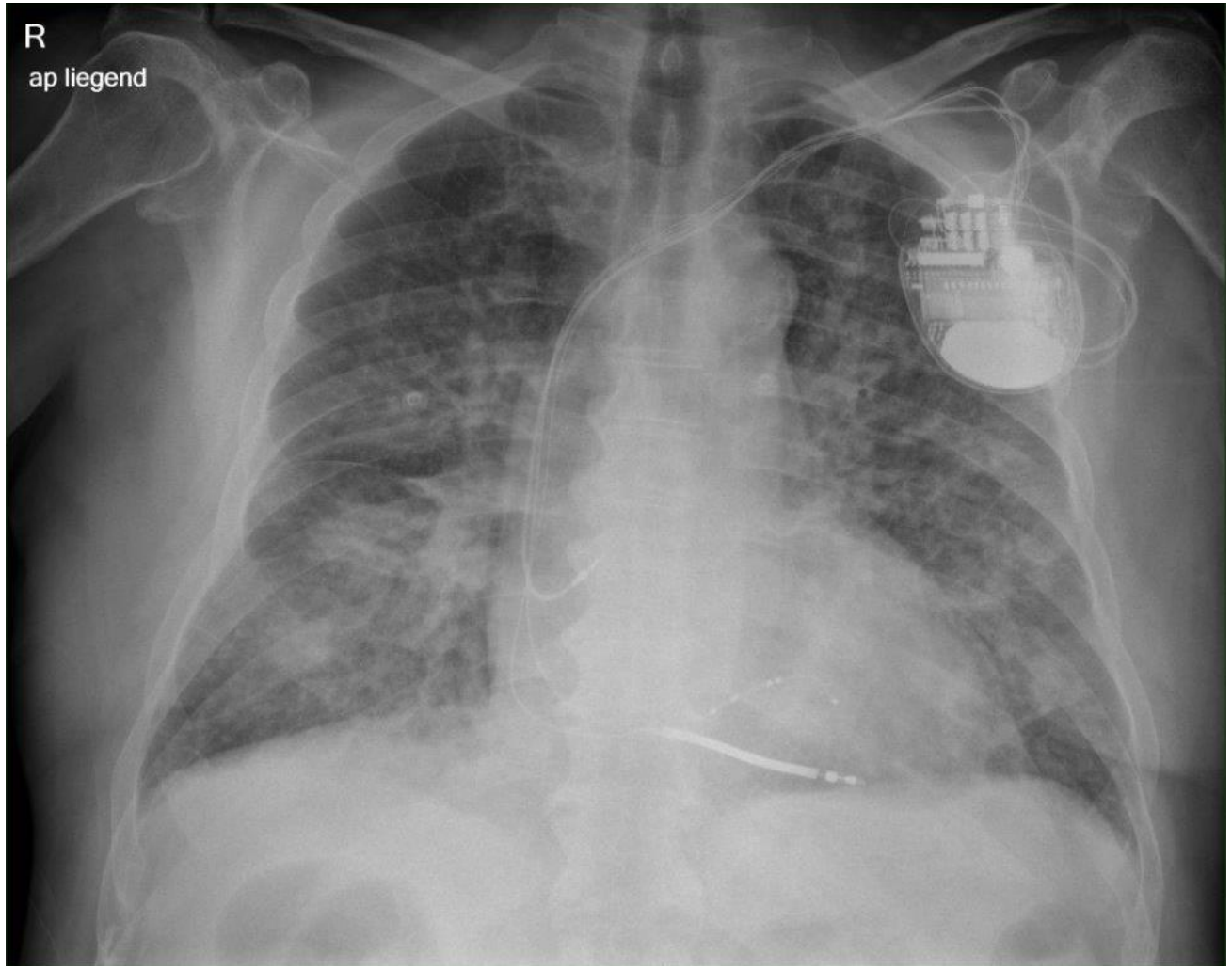

Azinäres Lungenödem

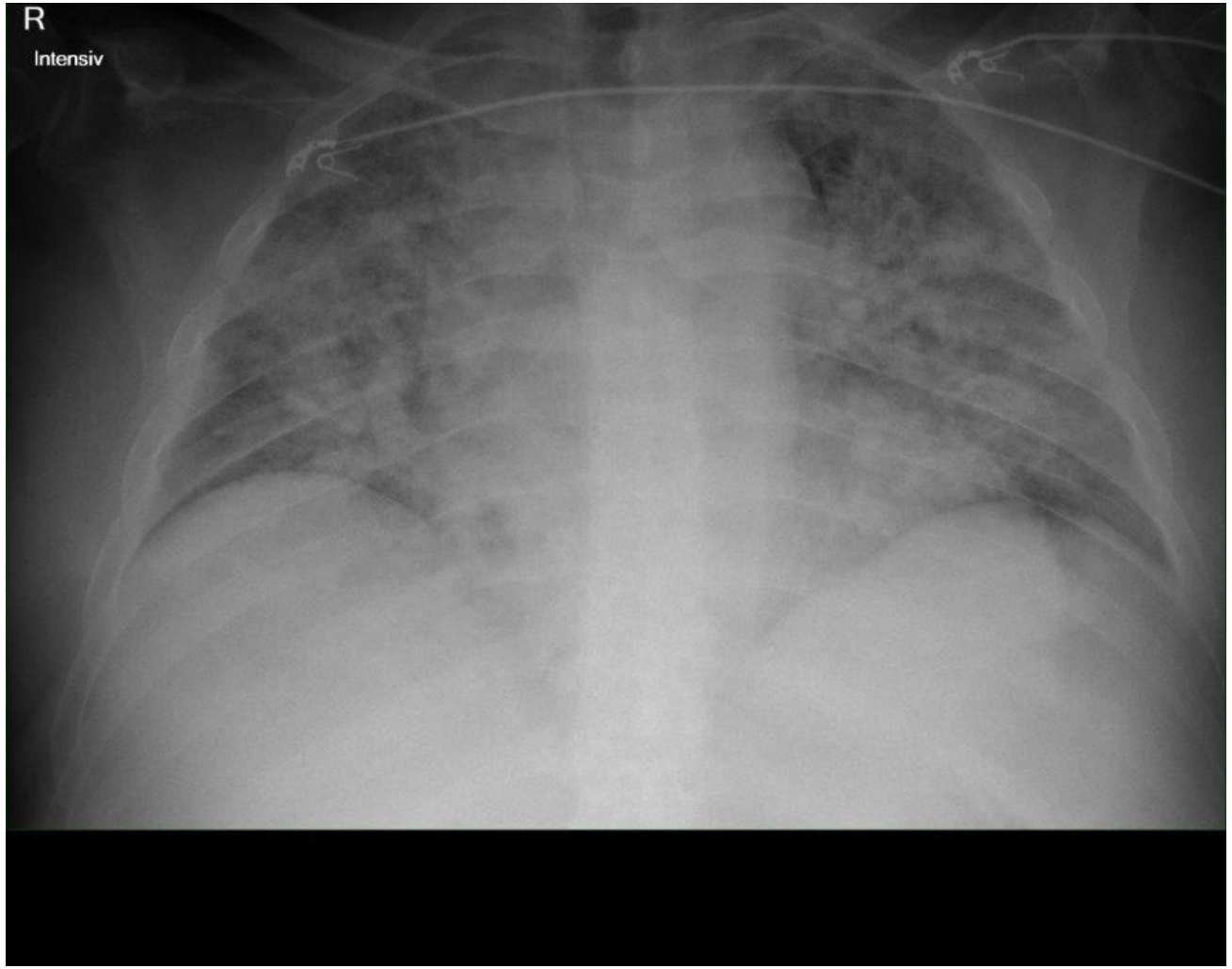

Zustand nach Rekompensation

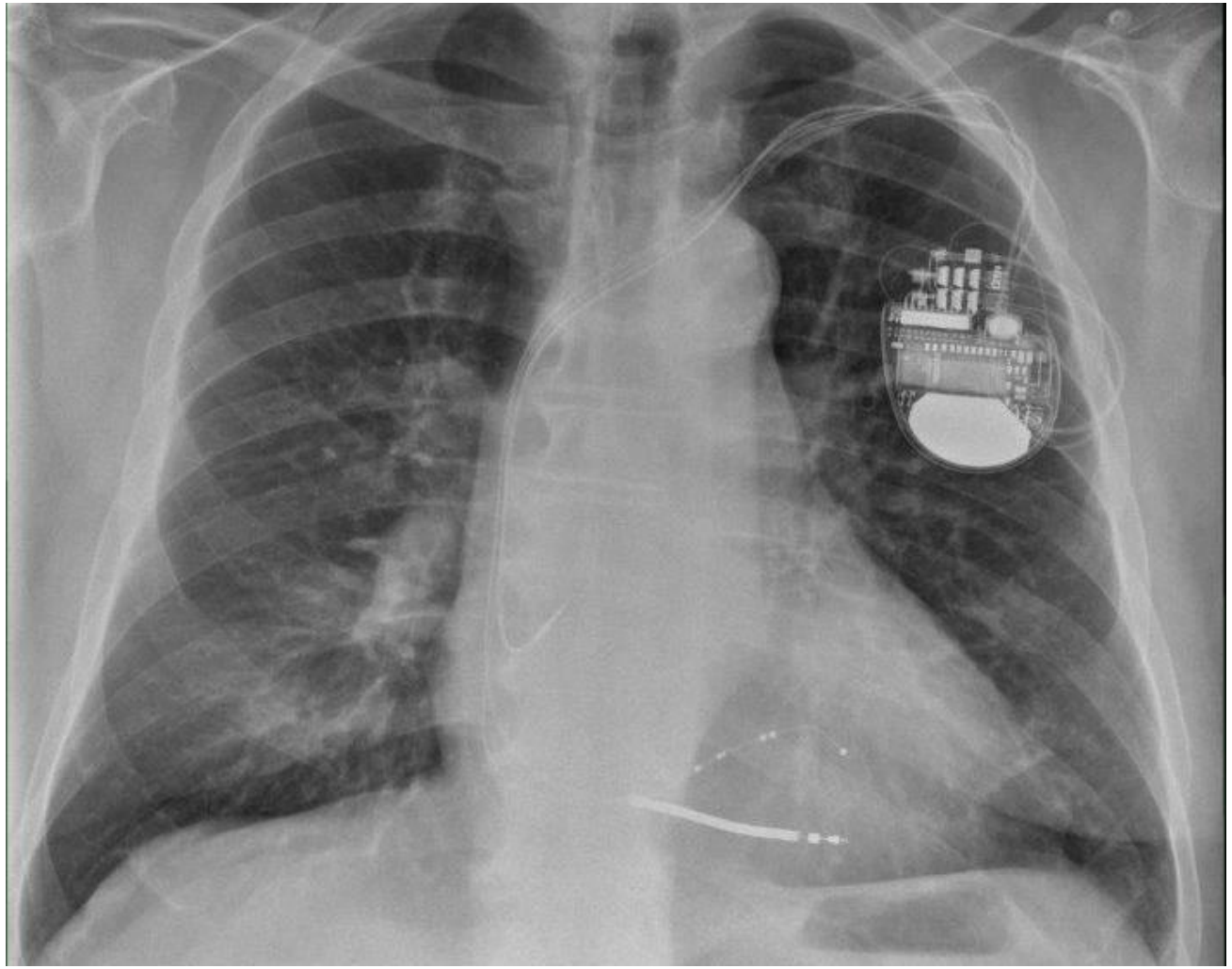

Kardiomyopathie

Diskrete Linksinsuff

Ödeme

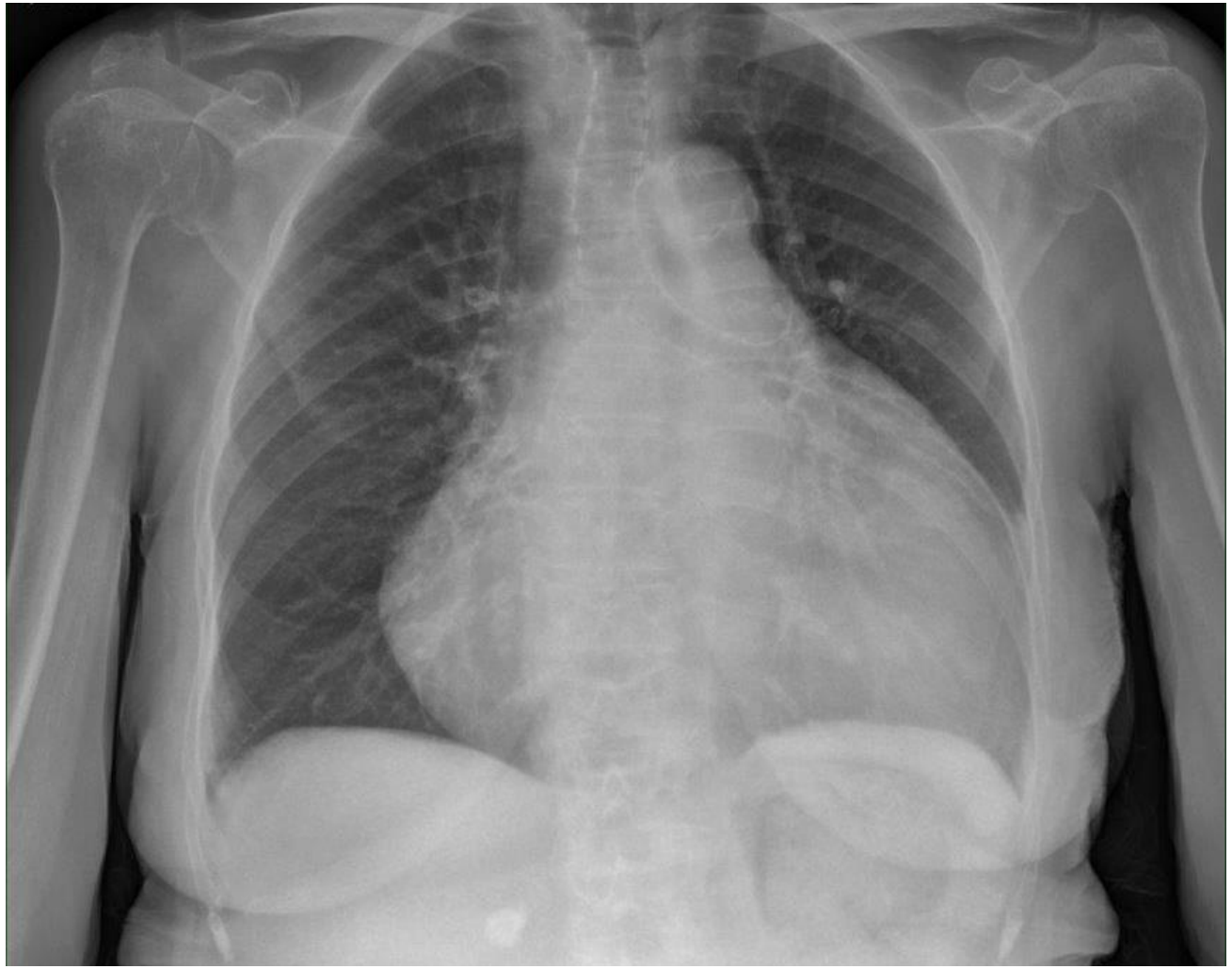

Lymphangiose

Ovarialkarzinom

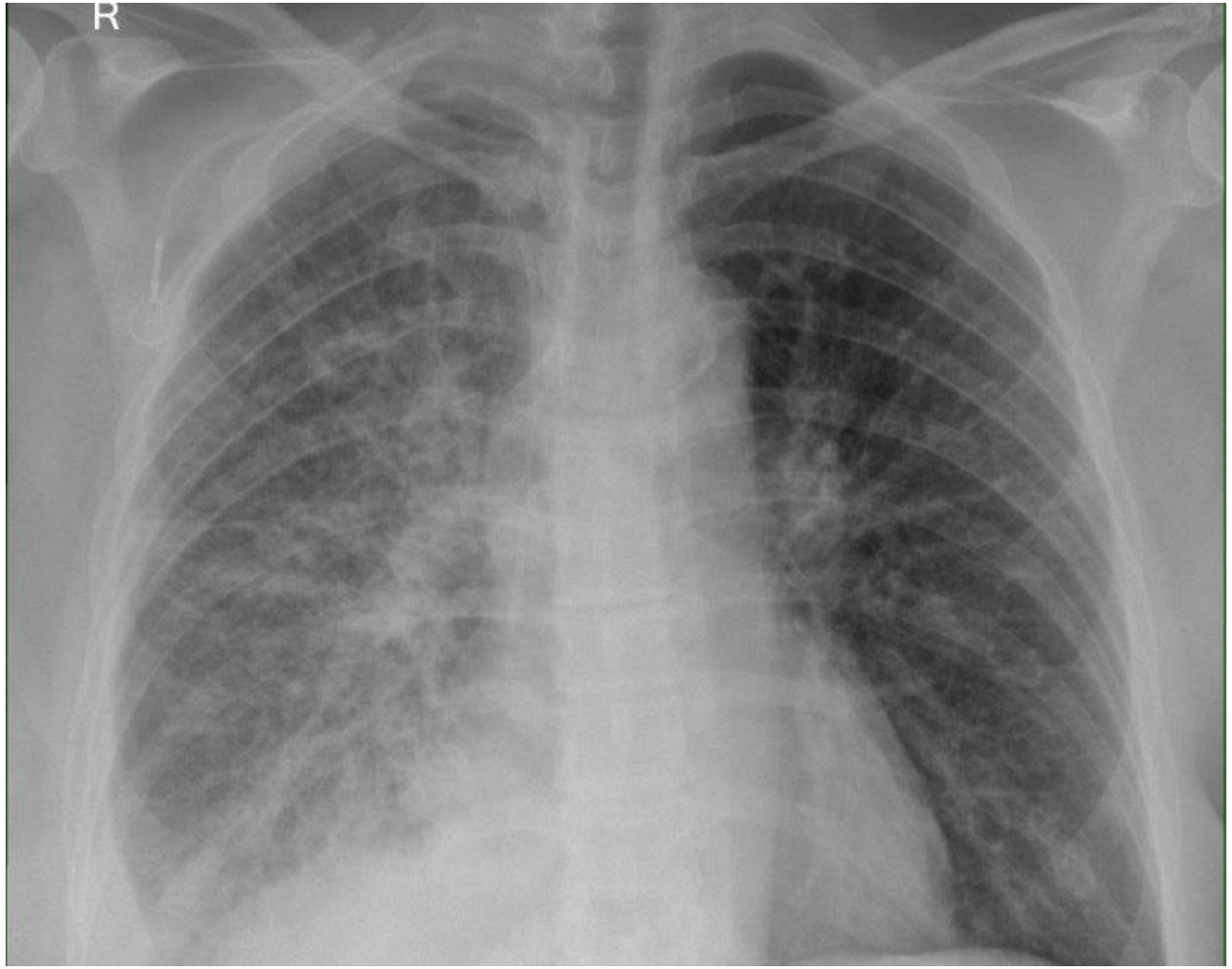

Cystische Fibrose

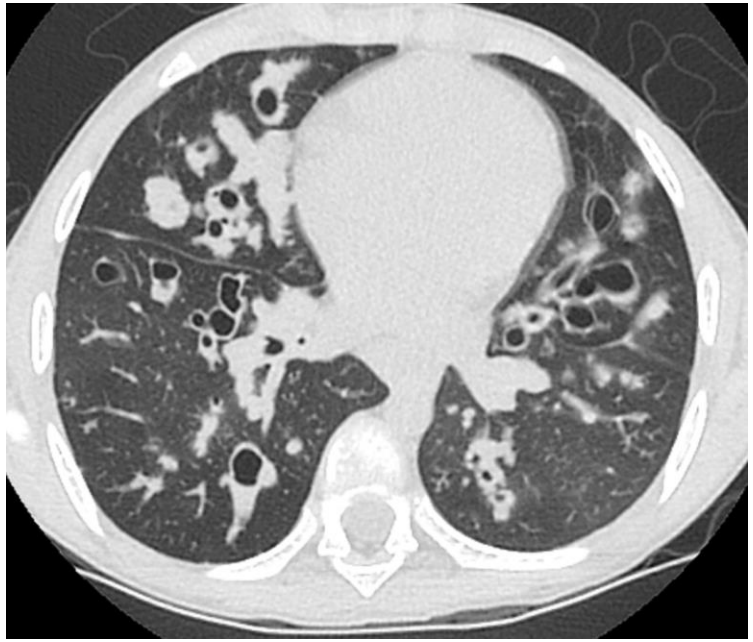

Bronchopulmonale Dysplasie

Bronchopulmonale Dysplasie

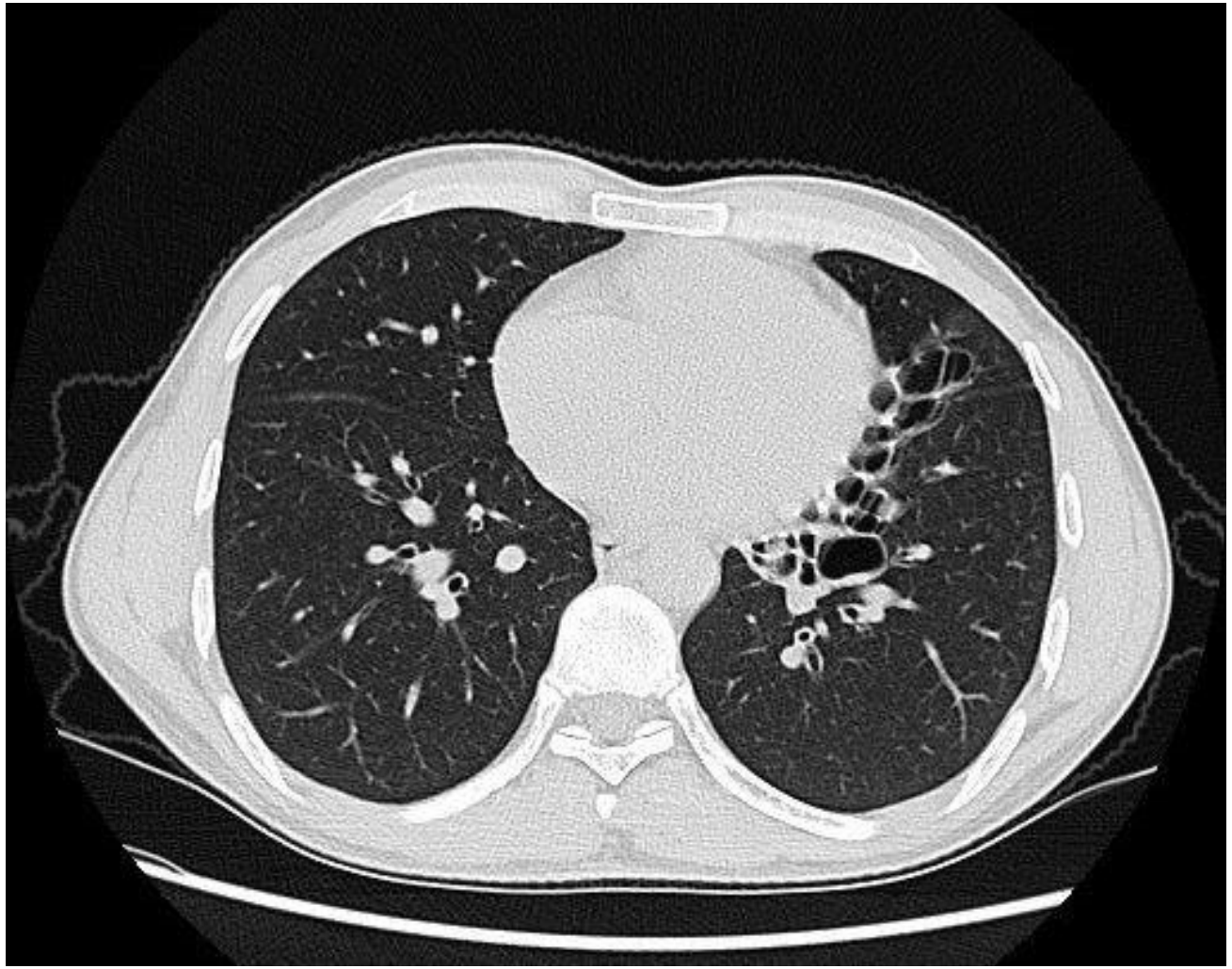

Pleura

Erguss

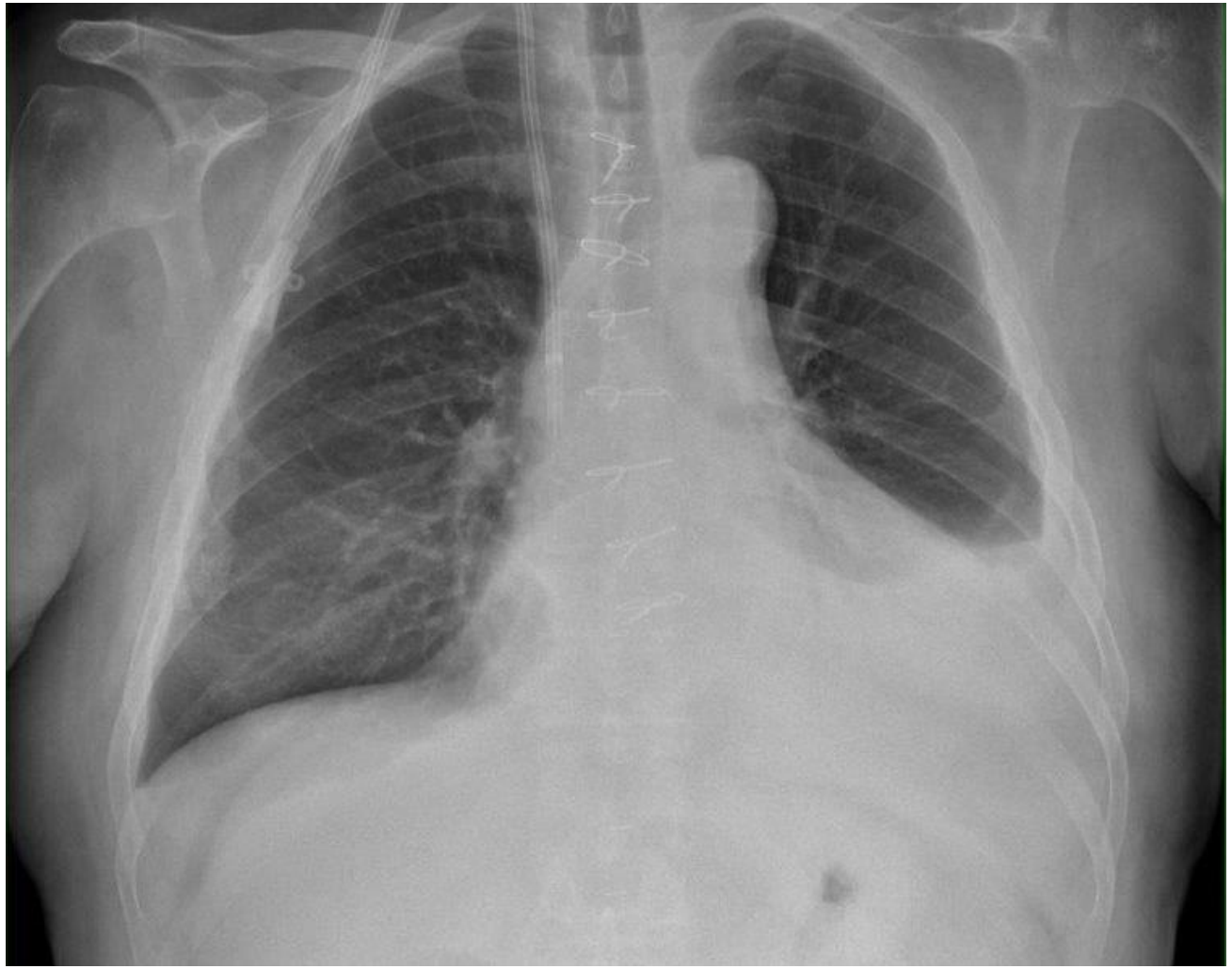

Pleuraerguss

Ein Zwerchfellschenkel fehlt

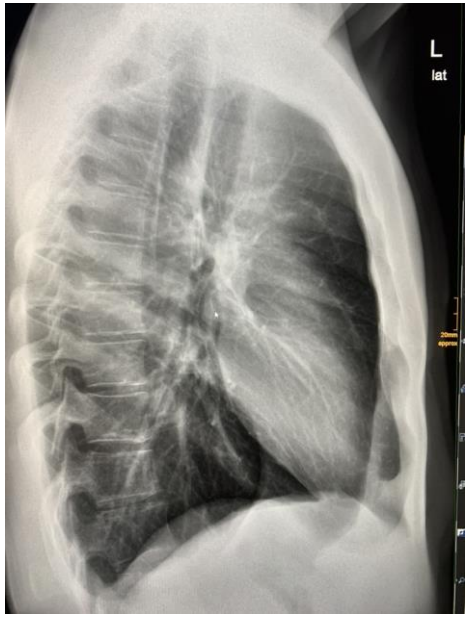

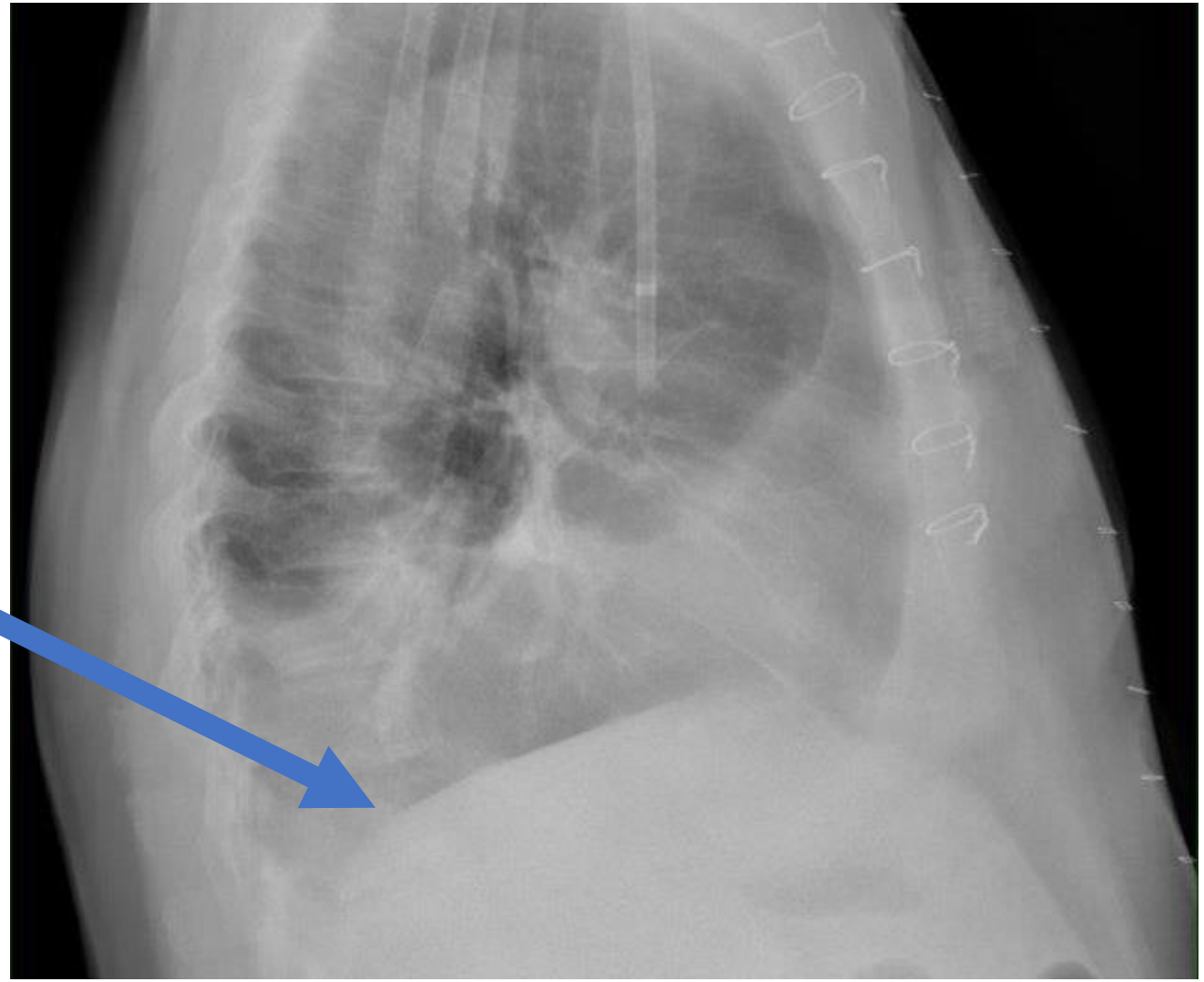

Pneumothorax

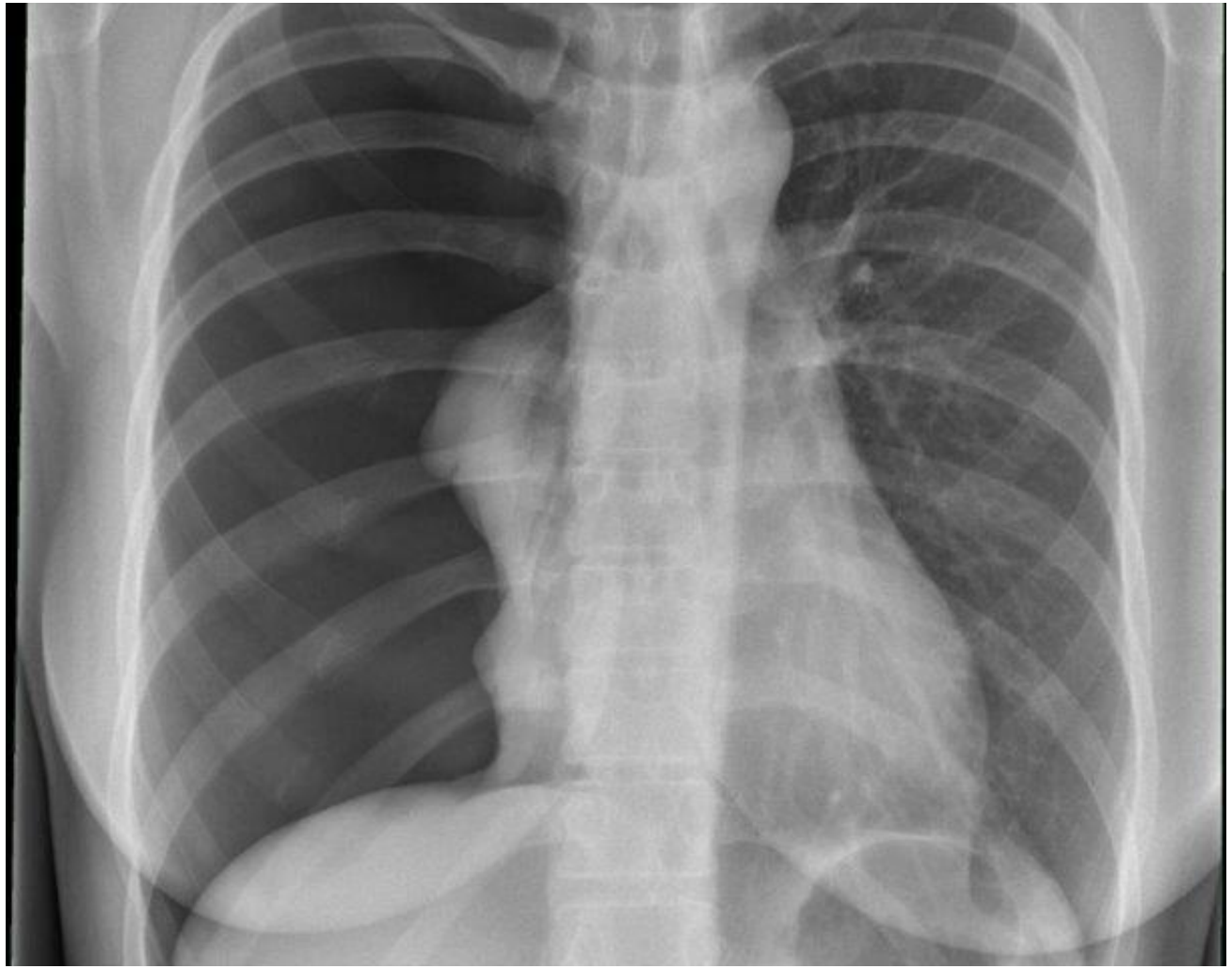

Hautemphysem
Mediastinalemphysem

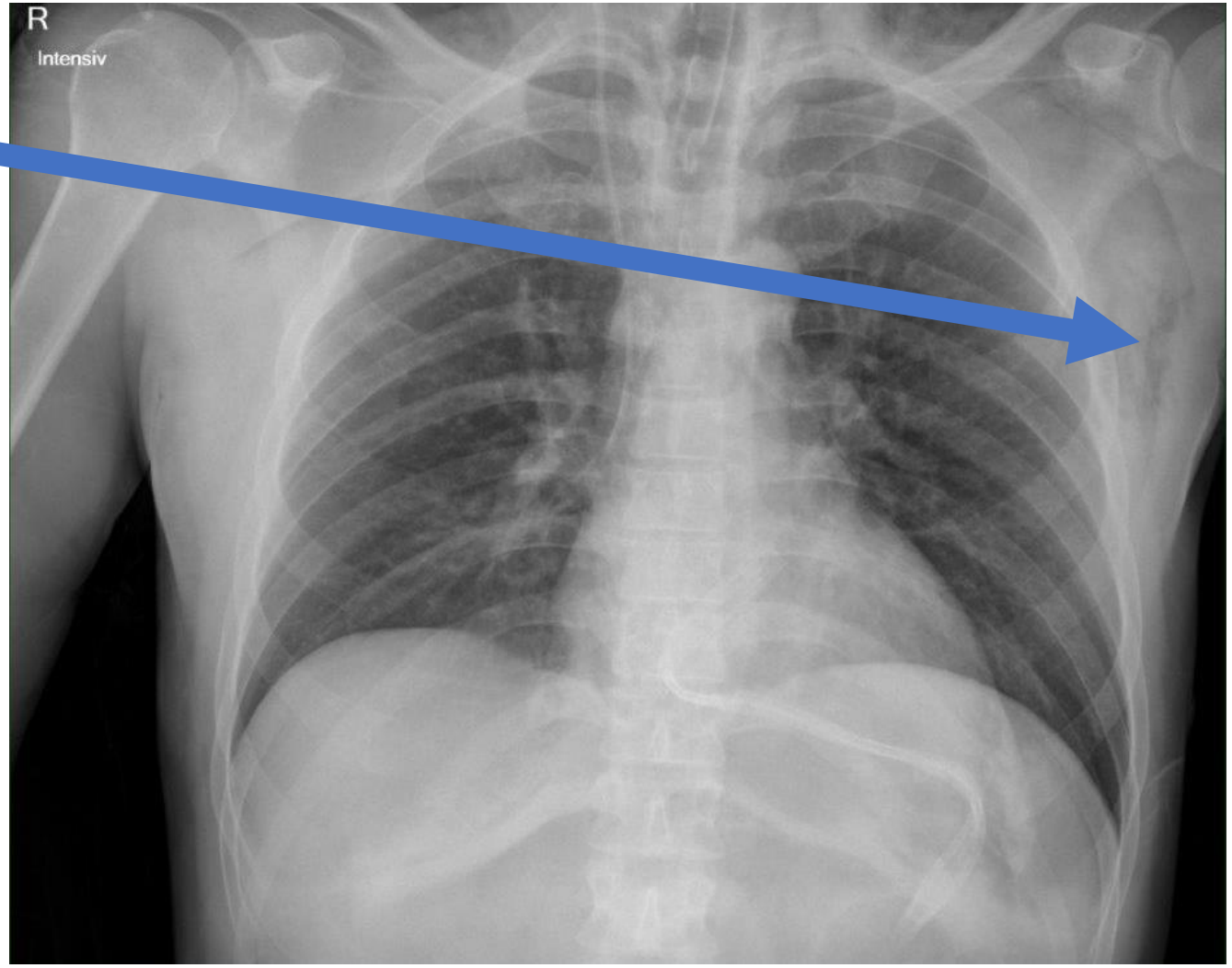

Hautemphysem
Mediastinalemphysem

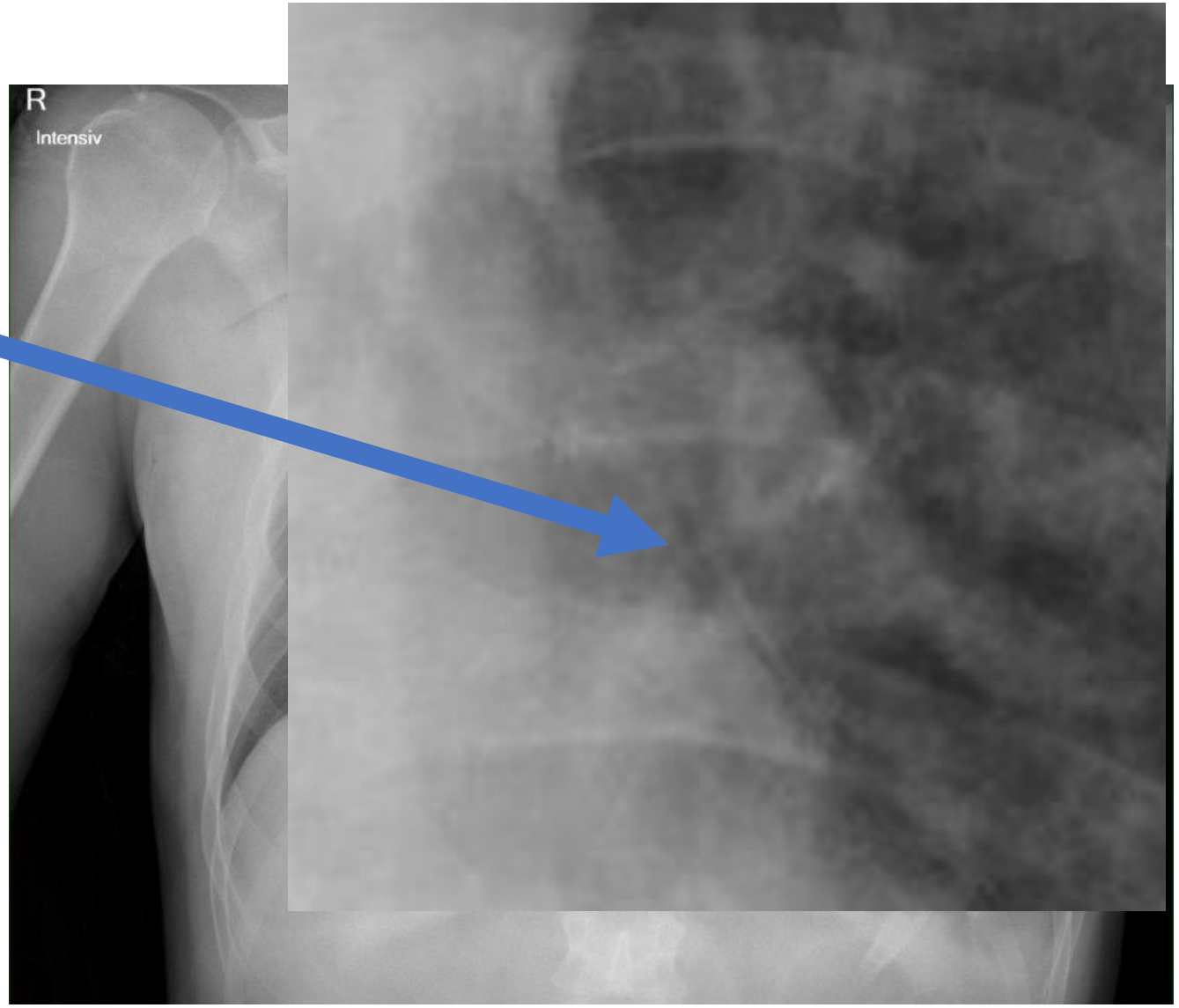

Deep sulcus sign

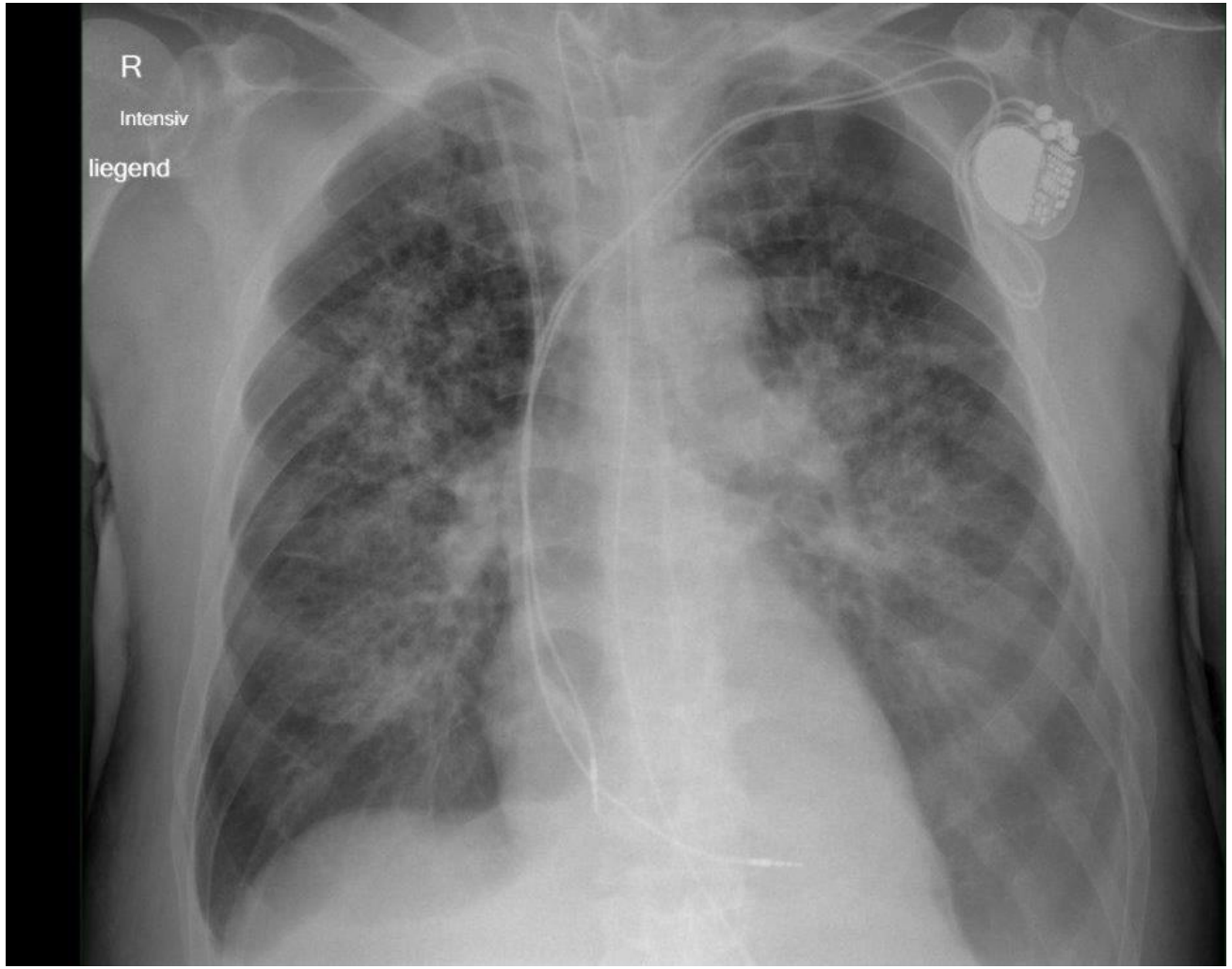

Deep sulcus sign

Erguß

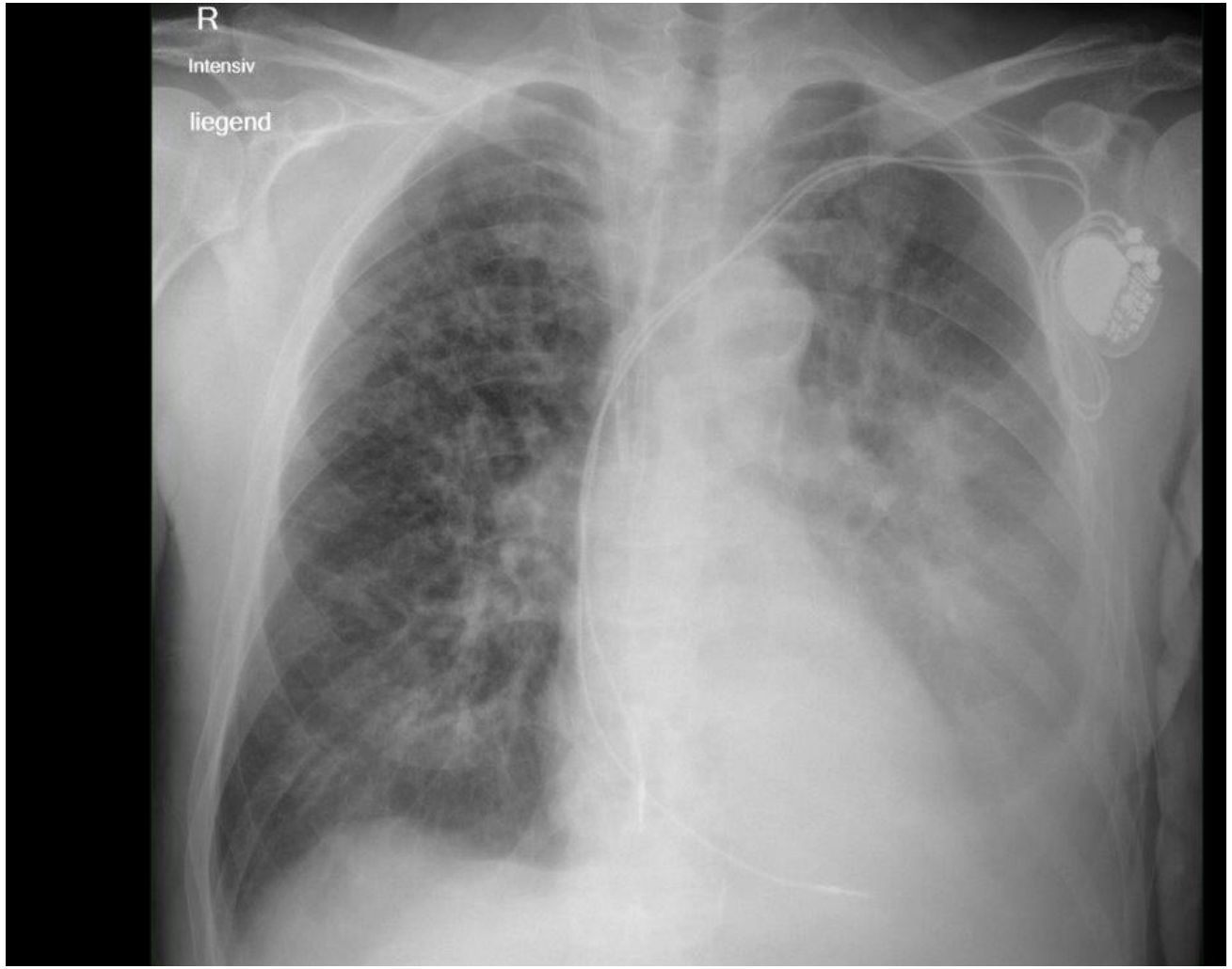

Deep sulcus sign

Erguß+

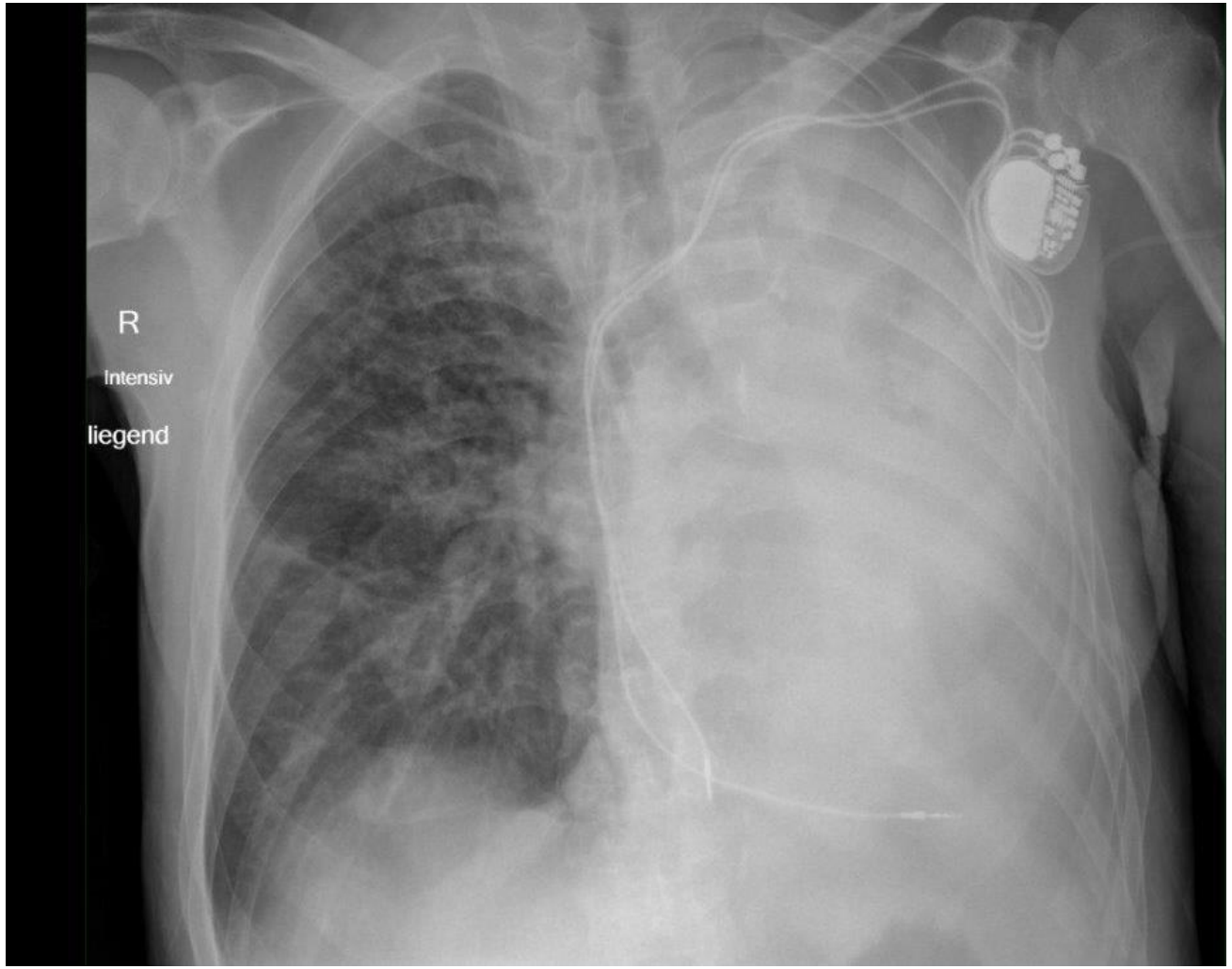

Deep sulcus sign

Erguß+

Pneumothorax

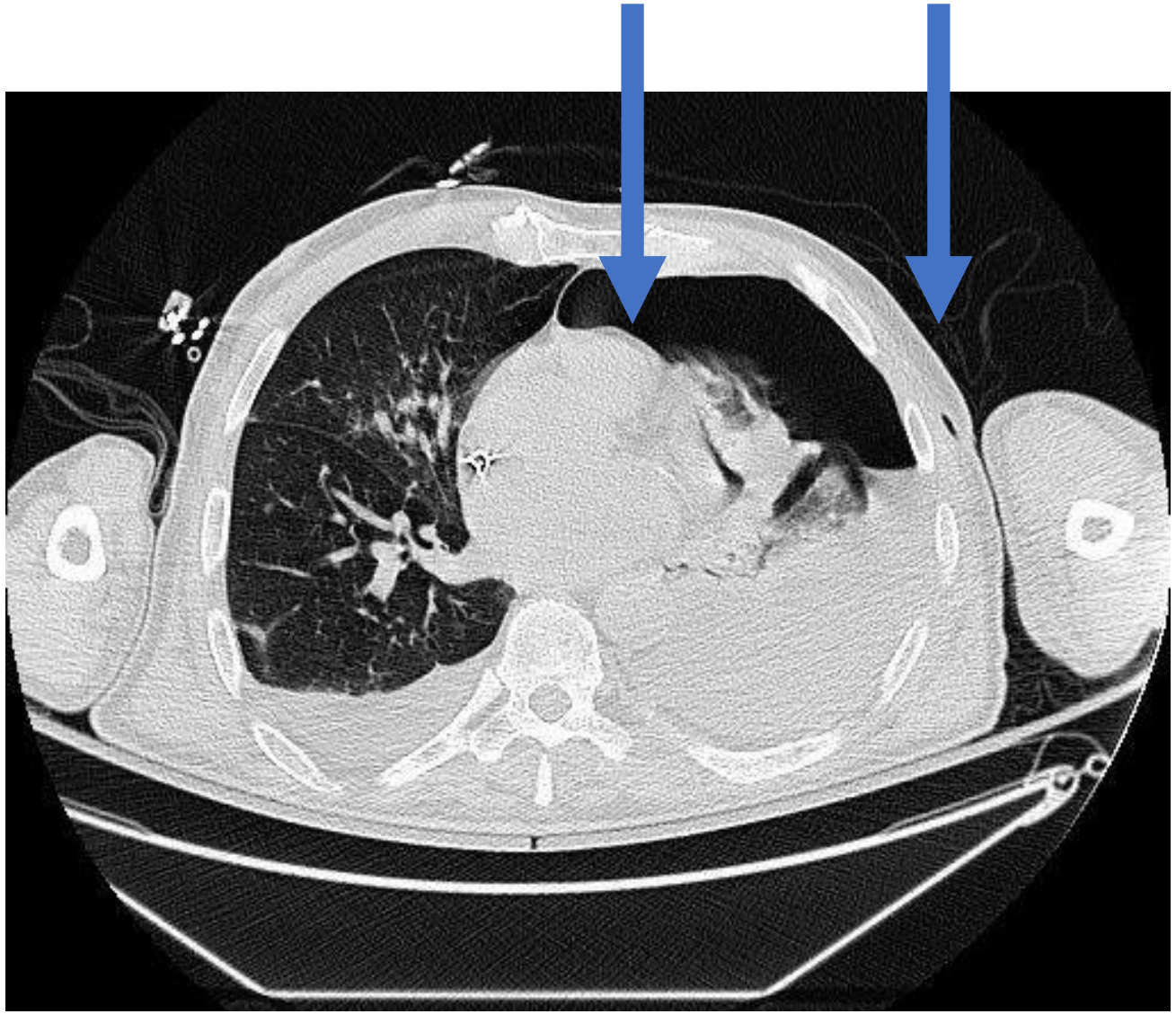

Pneumothorax

Expansionsödem

Von der „Entspannungsatelektase zur Resorptionsatelektase“

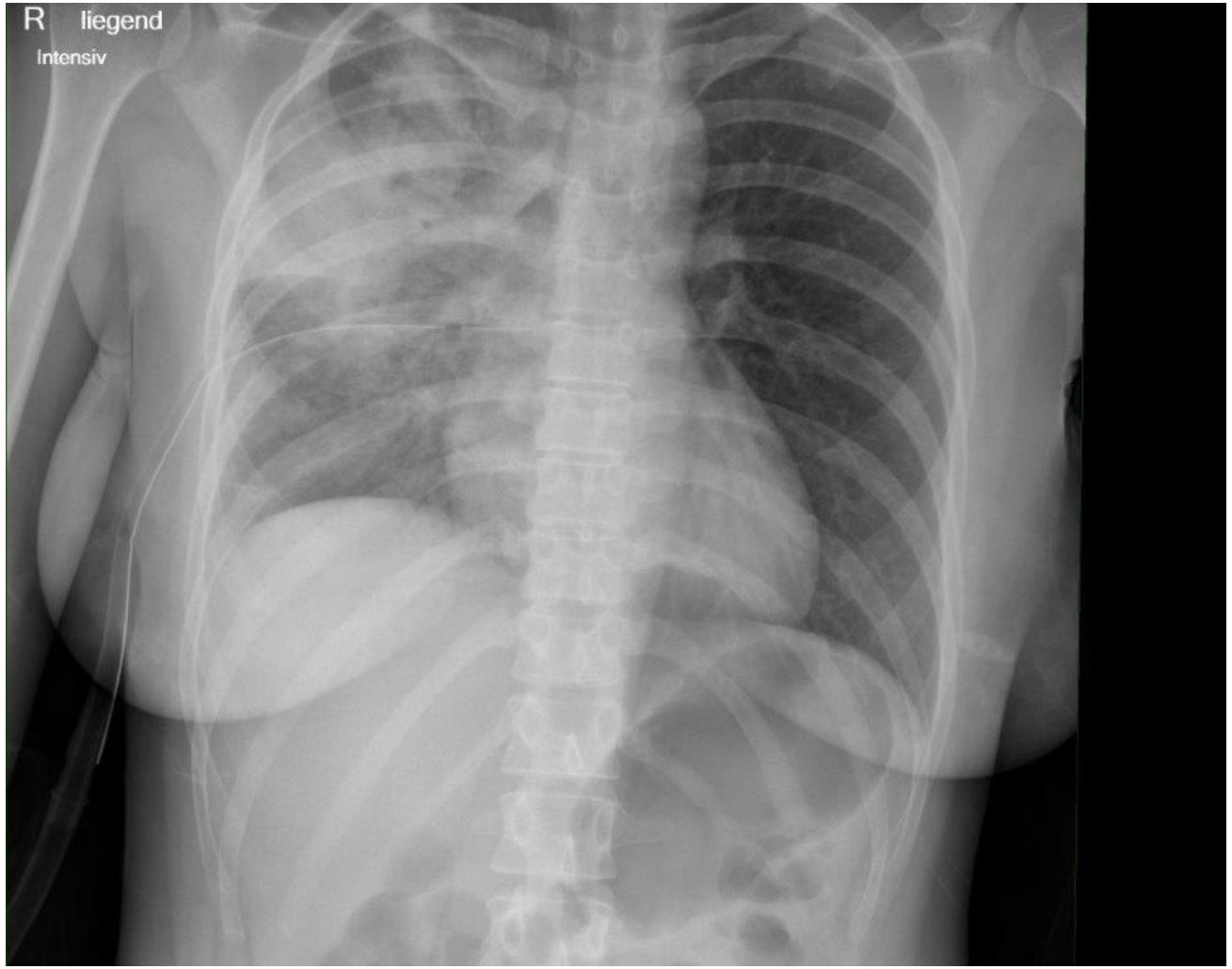

Pneumothorax

Expansionsödem

Von der „Entspannungsatelektase zur Resorptionsatelektase“

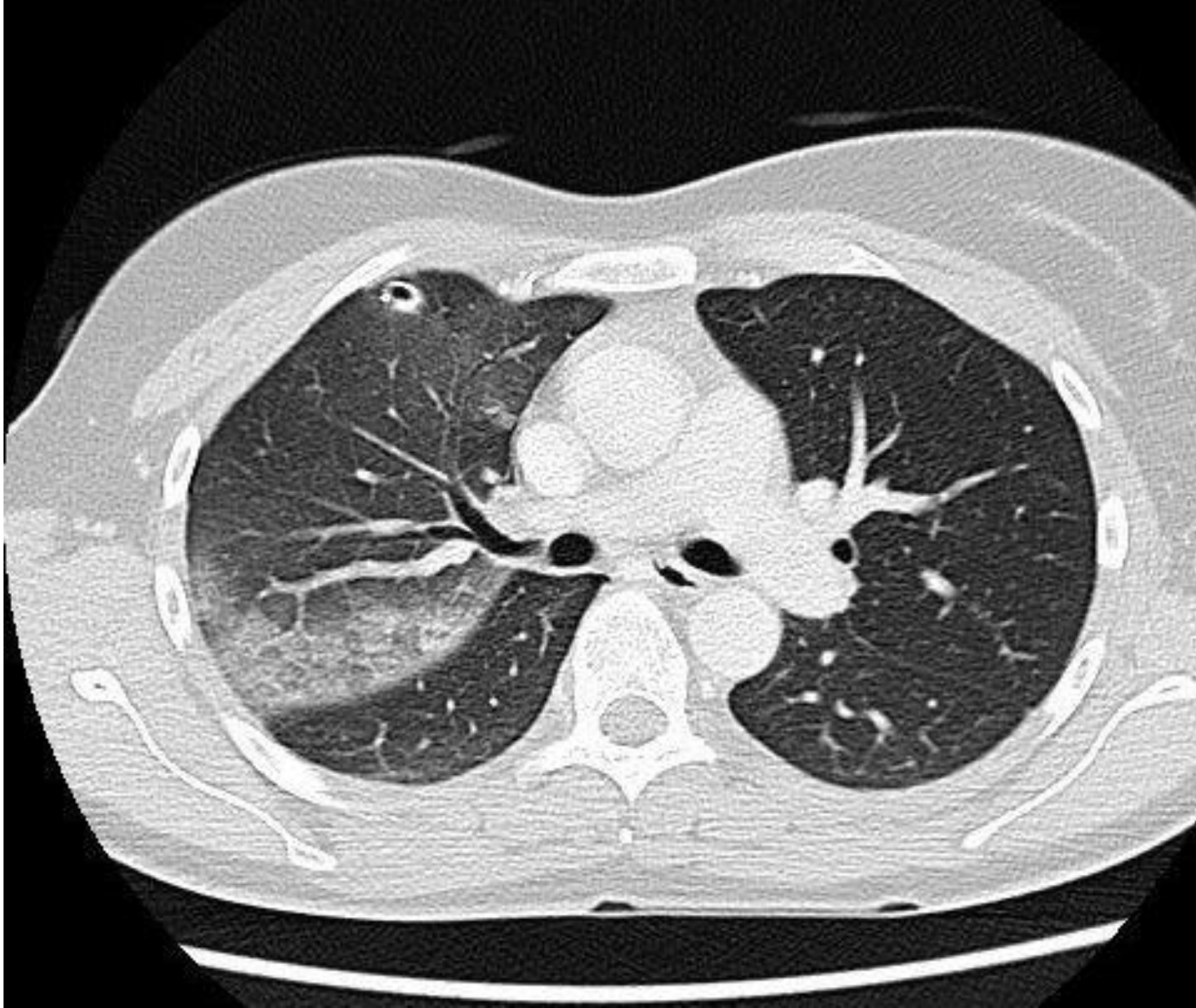

Atelektase

Oberlappenatelektase

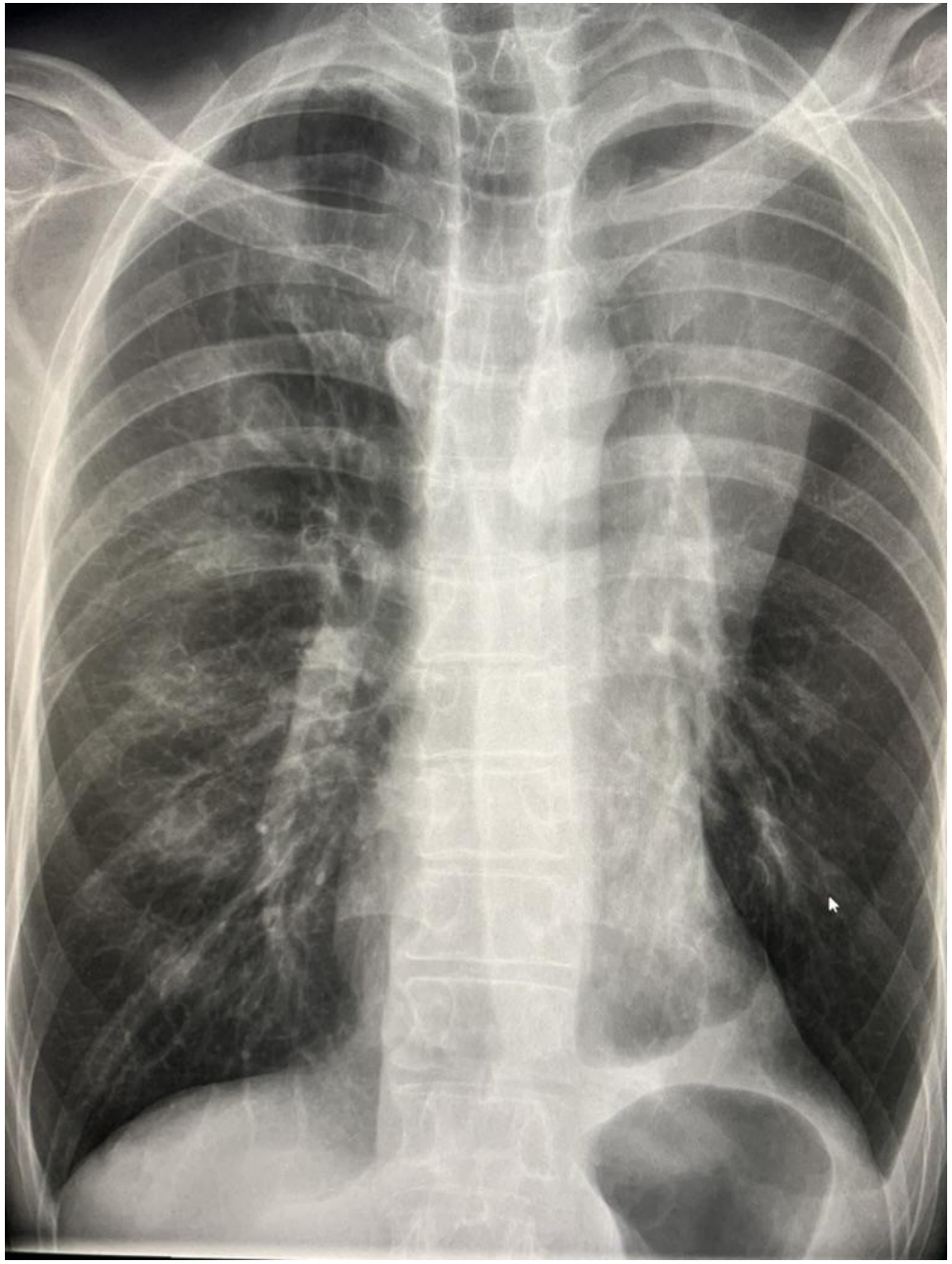

Oberlappenatelektase

Oberlappenatelektase

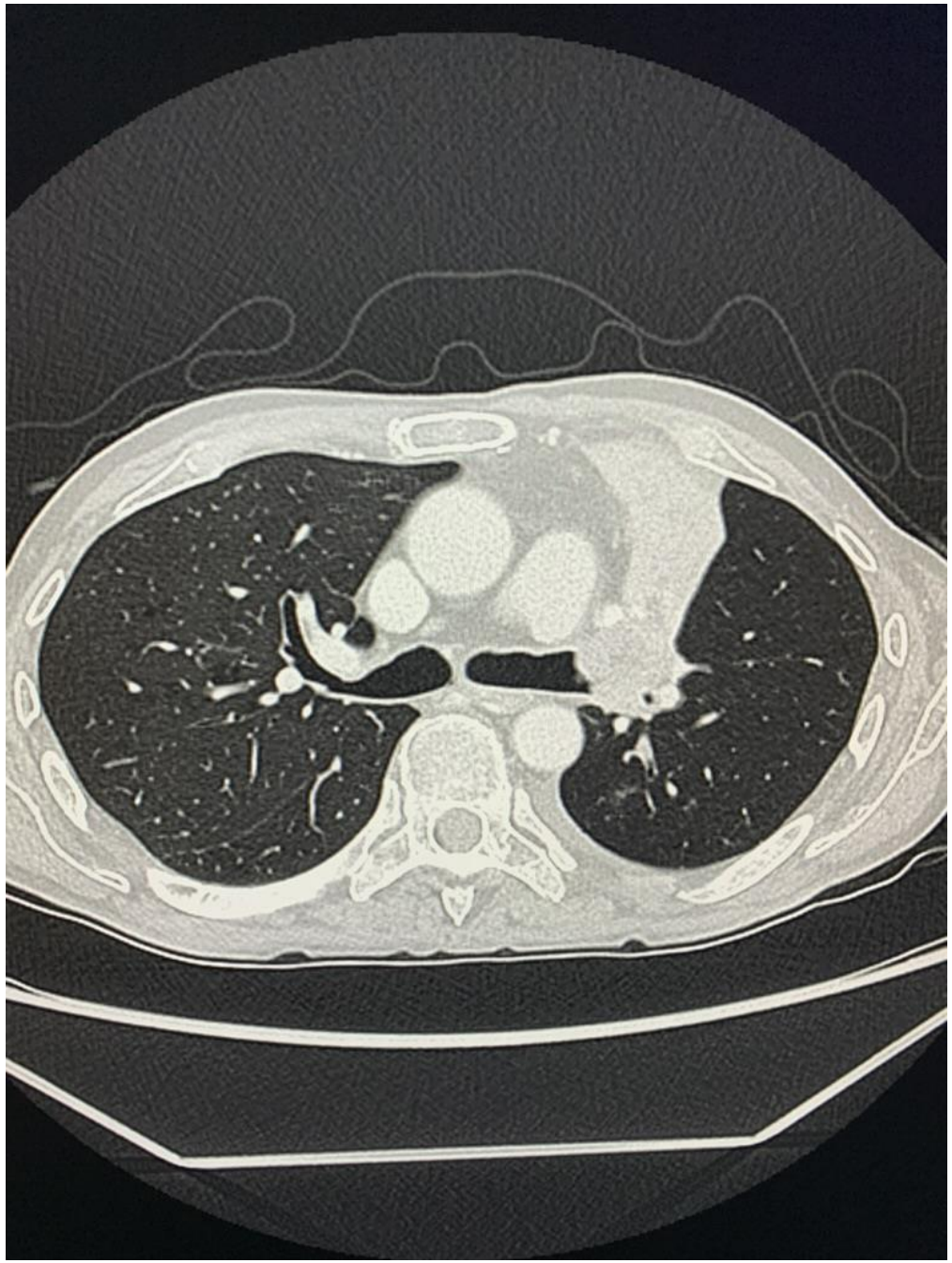

Tumor

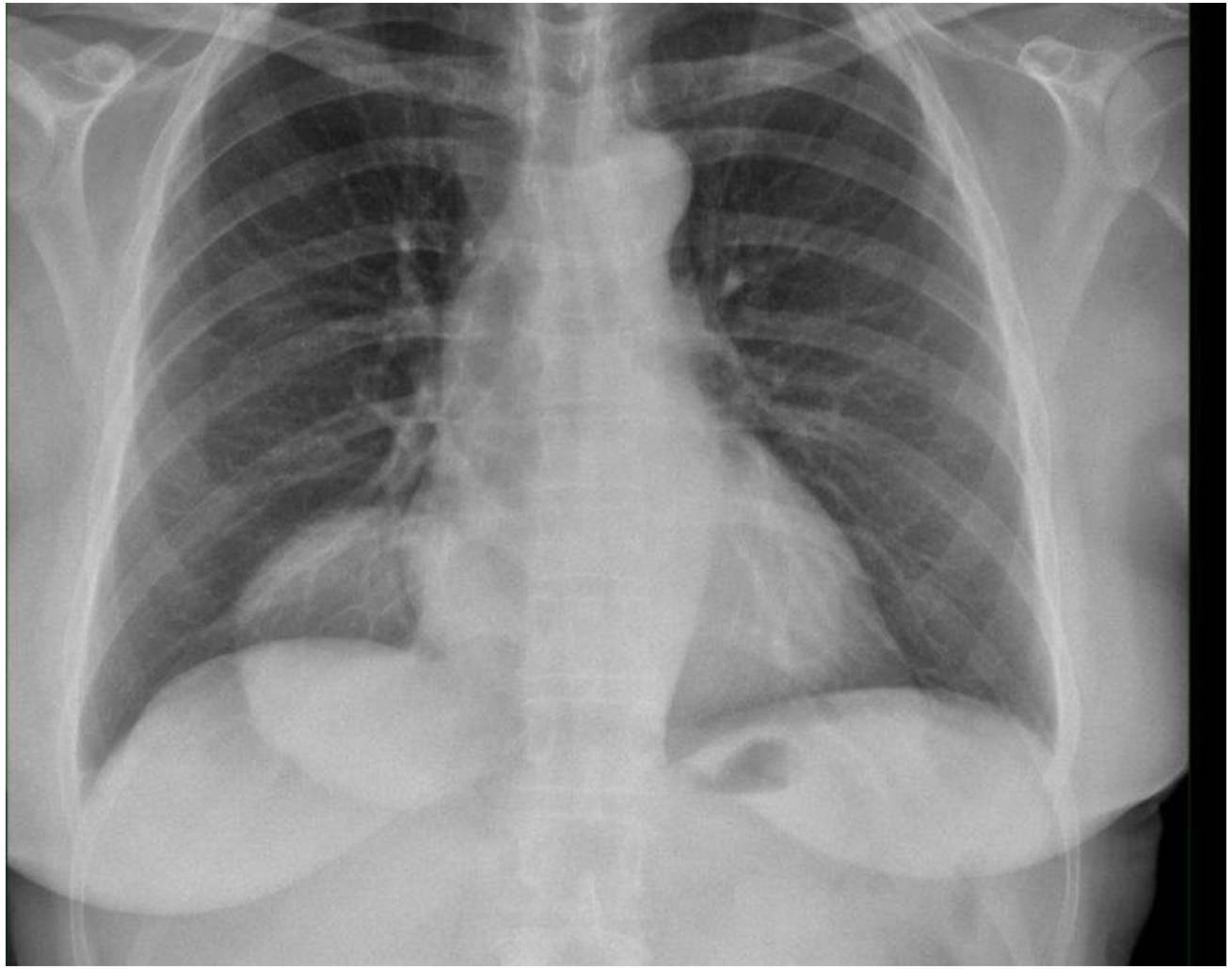

Tumor

Tumor
Kleinhirnmetastase

Npl bronchi

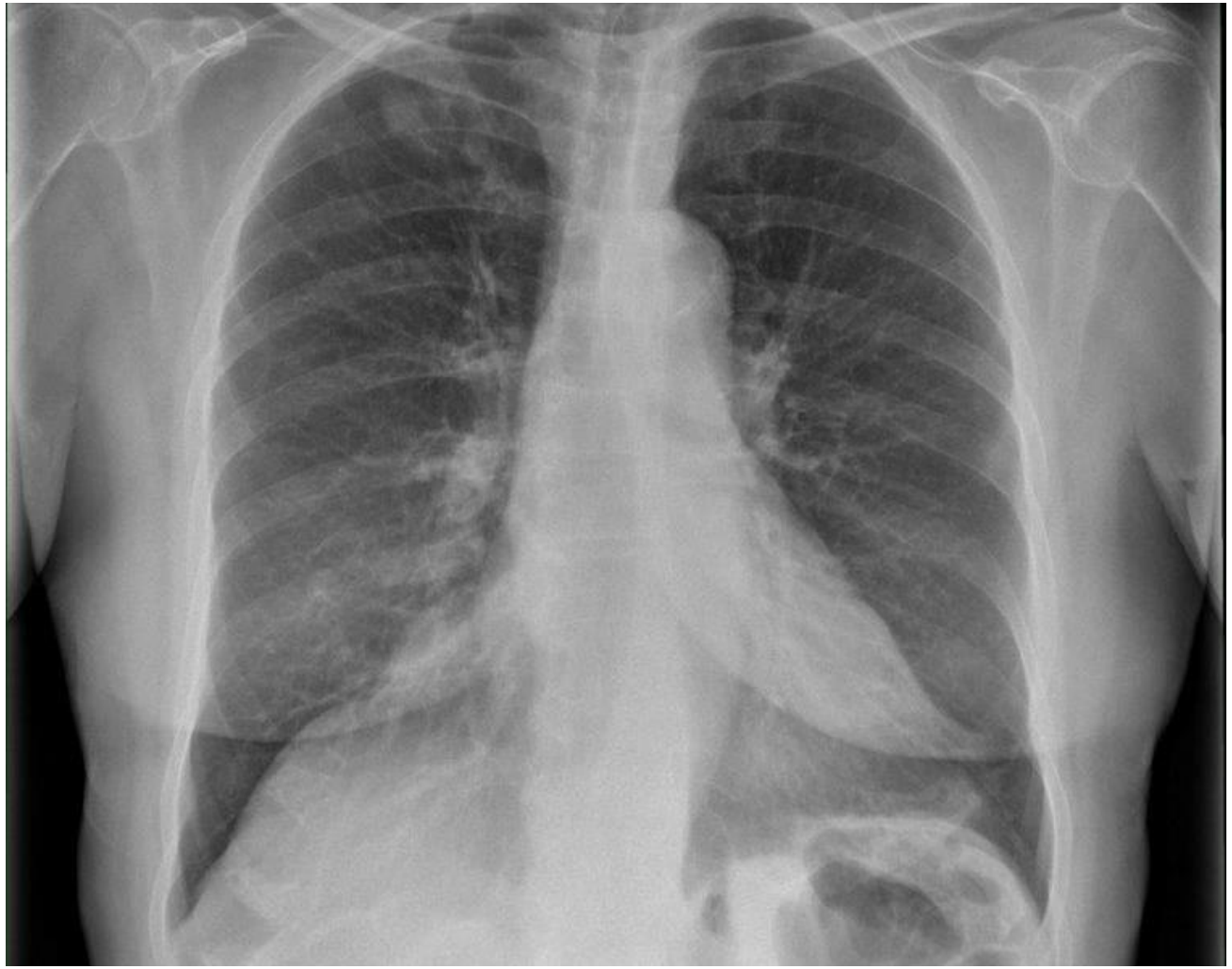

Npl bronchi

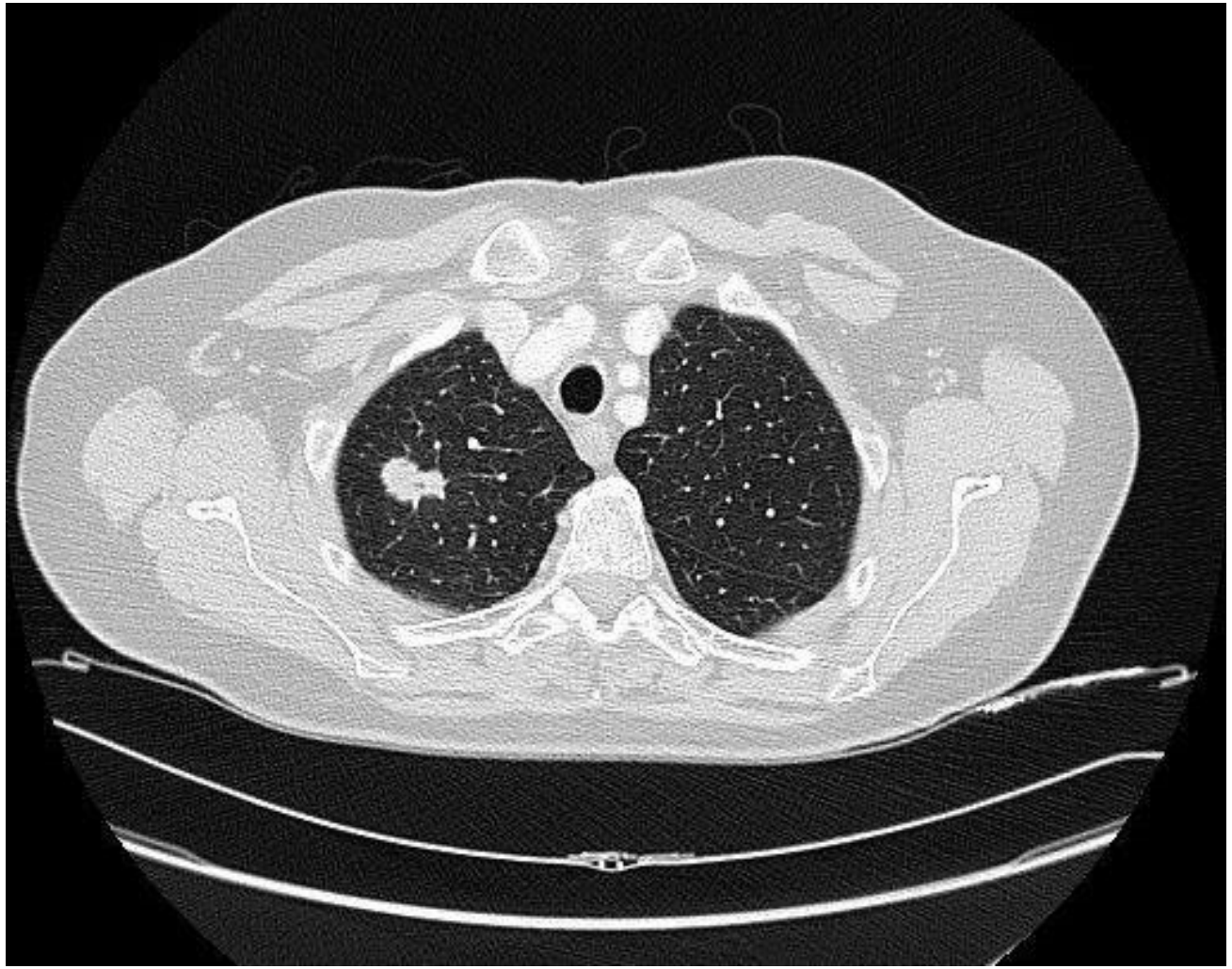

Npl bronchi

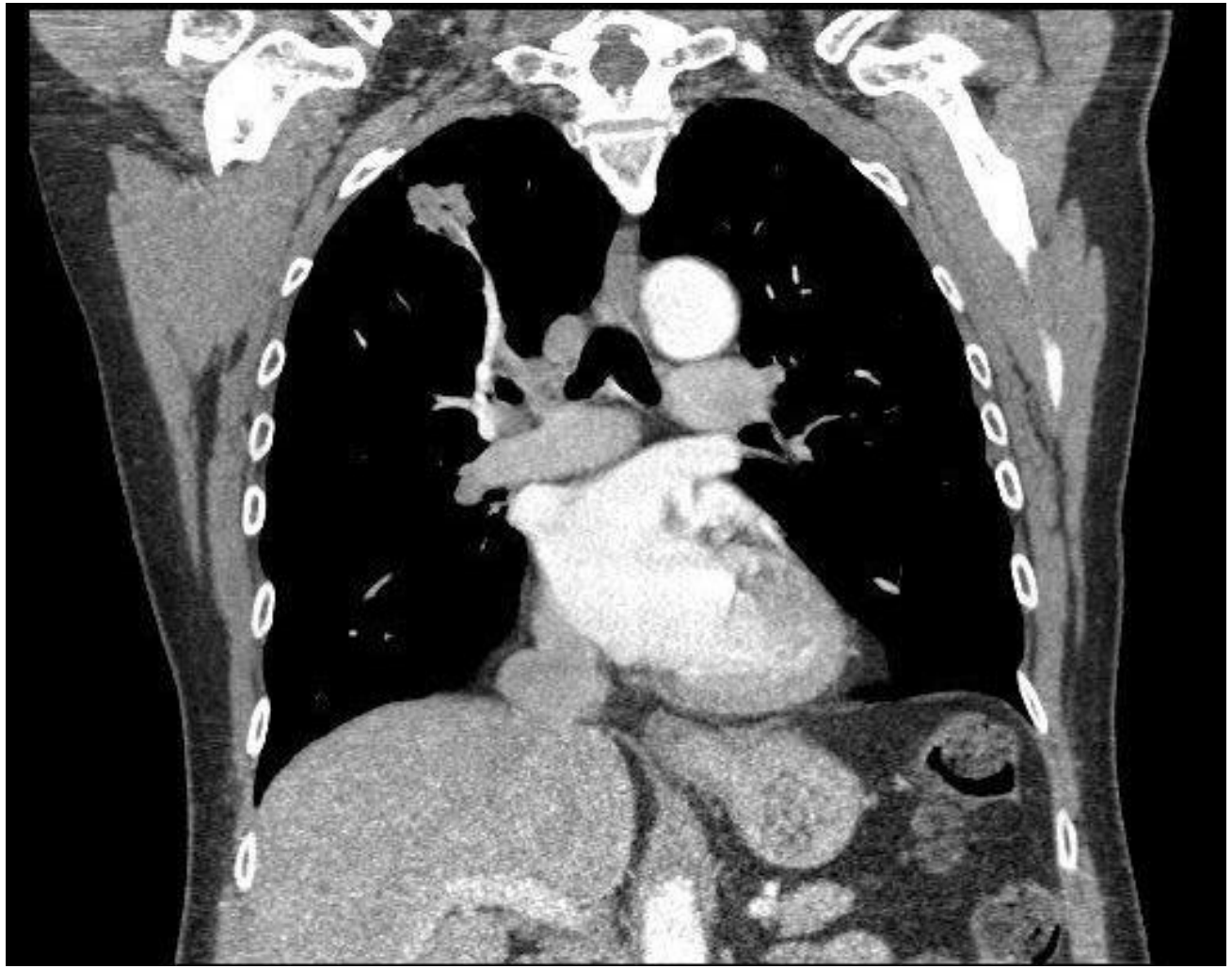

Infiltrate?

Trichterbrust

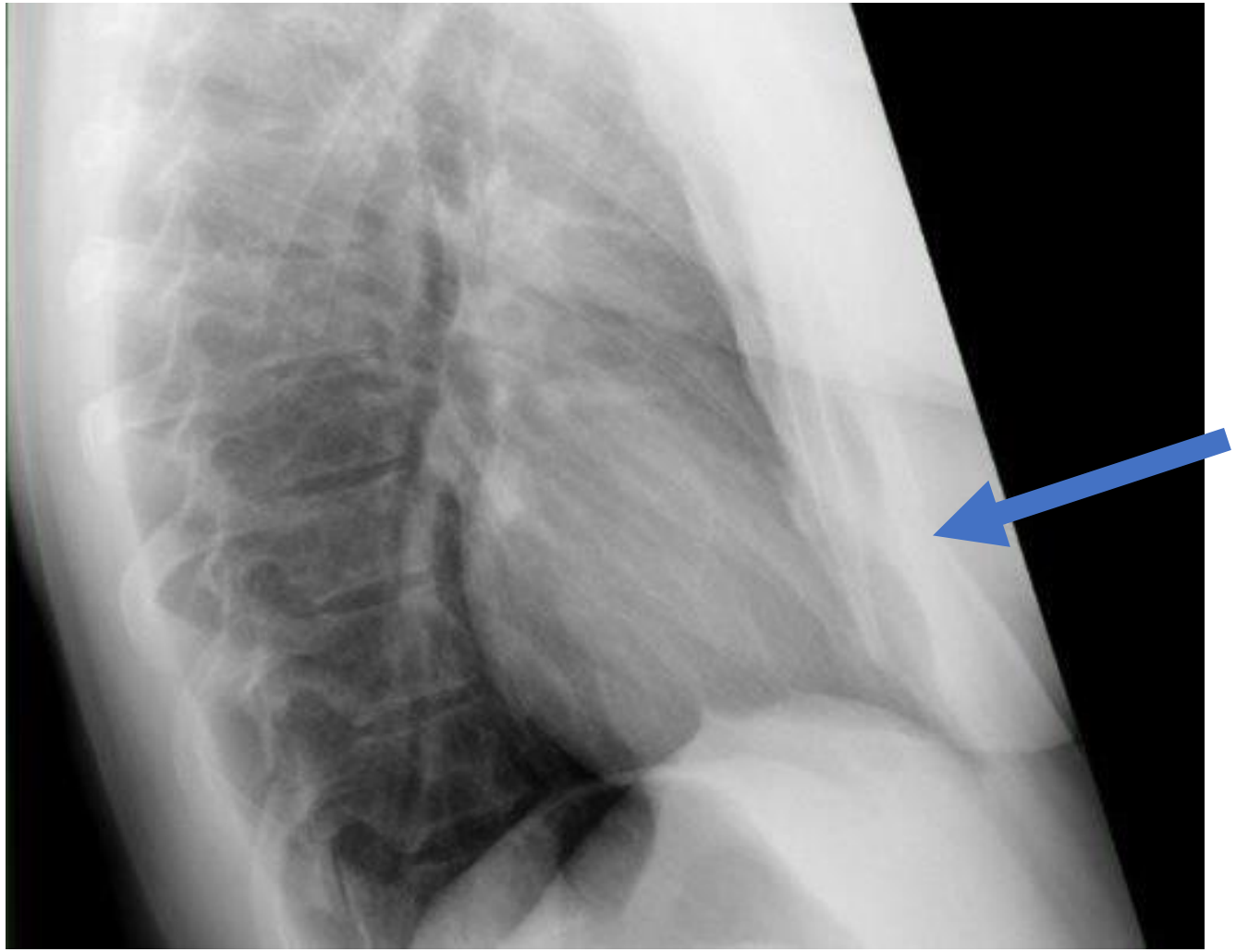

#Kommunikation

https://learn.meindfp.at/evaluate/org/44238808/courses/event_60079050/static/xolrn/F68A3C8A18506#60079428

1 Strahlenschutz und Sicherheit bei Kontrastmitteln

Autor: Dr. Thomas Mader

Einleitung

Der Einsatz von ionisierender Strahlung und von Kontrastmitteln in Nuklearmedizin und Radiologie ist ein integraler Bestandteil moderner medizinischer Diagnose- und Behandlungskonzepte.

Computertomographie, Radiographie (inkl. Mammographie), Durchleuchtung und Nuklearmedizin basieren auf der Anwendung ionisierender Strahlung, welche auch in der Lage ist, DNA zu schädigen und auf diesem Weg - bei unsachgemäßer Anwendung - das Risiko einer malignen Erkrankung (u.a. Leukämie, solide Tumore der Lunge, Schilddrüse, Brust, GI-Trakt, Haut) zu erhöhen.

Aus diesem Grund ist der schonende Umgang mit Strahlung zu priorisieren und für jede angeordnete Untersuchung vorab eine sorgfältige Nutzen-/Risiko-Analyse durchzuführen.

Die gesetzlichen Rahmenbedingungen, u.a. Dosisreferenzwerte, für die Strahlenanwendung werden durch das Strahlenschutzgesetz und die med. Strahlenschutzverordnung in der jeweils letztgültigen Fassung gebildet.

Es ist nicht möglich, in Bezug auf Sicherheit, alle Aspekte der Strahlen- und Kontrastmittelanwendung in Kürze zu behandeln. Dieses e-learning tool soll dazu aber eine Einführung bieten und erste wichtige Informationen vermitteln.

Dosisbestimmung

Biologische Effekte von Strahlung sind abhängig von der absorbierten Energie. Das Maß dafür ist 1 Gray (Gy), gemessen in Joule/kg.

Da exponierte Organsysteme eine jeweils unterschiedliche Sensibilität gegenüber absorbierter Strahlungsenergie aufweisen, werden spezifische Gewichtungsfaktoren kalkuliert. Hieraus ergibt sich die effektive Dosis in Sievert (Sv). Die Dosisangaben in Radiologie und Nuklearmedizin erfolgen typischerweise in mSv (1 Sv=1000mSv).

Für die Abschätzung typischer Dosiswerte und den Vergleich erforderlicher Effektivdosen diverser Untersuchungsverfahren dient diese Tabelle:

Untersuchungsart	Effektiv-dosis (mSv)	entspricht wie vielen Thoraxröntgen (1 Aufnahme)	entspricht der natürlichen Strahlenexposition in Österreich[1]
Effektive Dosis durch natürliche Strahlenquellen pro Jahr			ca. 2,5 mSv/a
Effektive Dosis durch natürliche Strahlenquellen pro Tag			0,007 mSv/d
periphere Extremitäten; DXA	0,01	ca. < 0,5	< 2 Tage
Thoraxorgane p.a.	0,02	1	ca. 3 Tage
Thoraxorgane lateral	0,04	ca. 2	ca. 1 Woche
Schädel (2 Ebenen)	0,07	ca. 3,5	ca. 10 Tage
BWS (2 Ebenen)	0,7	ca. 35	ca. 4 Monate
LWS (3 Aufnahmen)	1,3	ca. 65	ca. 0,5 Jahr
Becken a.p.	0,7	ca. 35	ca. 4 Monate
Abdomen a.p.	1	ca. 50	ca. 5 Monate
IVU (6 Aufnahmen)	2,5	ca. 125	ca. 1 Jahr
Schluckakt (24 Spot-aufnahmen, 106 sec. DL-Zeit)	1,5	ca. 75	ca. 8 Monate
CT Schädel	2,3	ca. 115	ca. 1 Jahr
CT Thorax	6	ca. 300	ca. 2,5 Jahre
CT Abdomen-Becken	10	ca. 500	ca. 4 Jahre
Lungenperfusionsszintigramm	0,8	ca. 40	ca. 4 Monate
Nierenszintigramm	1	ca. 50	ca. 5 Monate
Schilddrüsenszintigramm	1	ca 50	ca. 5 Monate
Knochenszintigramm	4	ca. 200	ca. 1,5 Jahre
Myokardszintigraphie*	5 – >20	ca. 250 - >1000	ca. 2 - >8 Jahre
PET (F-18 FDG)	5,5	ca. 300	ca. 2,5 Jahre
Perkutane koronare Intervention (PCI)	17**	ca. 850	ca. 7 Jahre

Risiken

Deterministische Schäden treten erst oberhalb einer gewissen Schwellendosis auf und steigen mit weiterem Dosisanstieg stark an. Unterhalb der Schwellendosis sind allerdings keine Schäden zu befürchten. Beispiele dafür sind: Panzytopenie Infektrisiko, Erythem und Haarausfall, aber auch Schäden während der Organogenese des Ungeborenen. Deterministische Schäden sind

1 Strahlenschutz und Sicherheit bei Kontrastmitteln

1.1 Übungsfragen

Welche unerwünschten Effekte nach Strahlenanwendung zählen nicht zu den deterministischen Schäden:

- Erythem
- Katarakt
- Leukämie
- Solide Tumore
- Haarausfall

(2 Antworten)

Antwort überprüfen

Wieviel mSv entspricht ein Sievert:

- 100
- 10
- 1000
- 10000

(1 Antwort)

Antwort überprüfen

Welche Nebenwirkung kann bei Gadolinium-basierten Kontrastmitteln theoretisch auftreten:

- Schwere allergische Reaktion
- Thyreotoxikose
- Nephrogene systemische Fibrose

(2 Antworten)

Antwort überprüfen

Hier geht es weiter: 2 Interventionelle Radiologie

Radiologie für Zuweiser auf 26 Seiten

Suchen

Strong Medicine
@StrongMed
578.000 Abonnenten

Abonnieren

ÜBERSICHT | VIDEOS | PLAYLISTS | COMMUNITY | KANÄLE | KANALINFO | chest

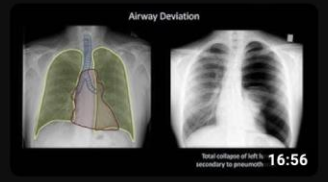

INTERPRETING CHEST X-RAYS
How to Interpret a Chest X-Ray (Lesson 4 - Airways, Bones, and Soft Tissues)
Strong Medicine 415.602 Aufrufe • vor 9 Jahren
An overview of how to assess the airways, bones, and soft tissues on chest X-ray, including the important etiologies of common radiographic abnormalities. Video includes following images (among...

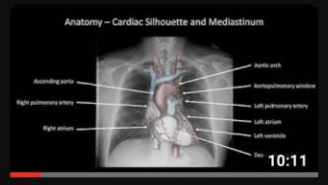

INTERPRETING CHEST X-RAYS
How to Interpret a Chest X-Ray (Lesson 2 - A Systematic Method and Anatomy)
Strong Medicine 1,1 Mio. Aufrufe • vor 9 Jahren
A description of a systematic method for examining a chest X-ray, and a review of the relevant thoracic anatomy.

Interpreting Chest X-Rays
Strong Medicine
How to Interpret a Chest X-Ray (Lesson 1 - An Introduction) • 14:24
How to Interpret a Chest X-Ray (Lesson 2 - A Systematic Method and Anatomy) • 10:11
KOMPLETTE PLAYLIST ANSEHEN

INTERPRETING CHEST X-RAYS
How to Interpret a Chest X-Ray (Lesson 1 - An Introduction)
Strong Medicine 485.344 Aufrufe • vor 9 Jahren
An introduction to the interpretation of chest X-rays, covering the basic principles of using X-rays in medical imaging, as well as the conventional X-ray views (i.e. PA, lateral, and AP).